

Continuum of care in hard-to-heal wounds by copper dressings: a case series

Published December 2023



The quest for an ideal wound dressing has been a challenge due to the complex nature of wound healing, including stages of haemostasis, inflammation, maturation, and remodeling, making it difficult to find a single dressing that optimally supports all phases of wound healing. The ideal wound dressing should possess antimicrobial properties and be capable of effectively debriding and lysing necrotic tissue stimulate all key essential all physiological wound healing processes. Copper, an essential trace element, participates in many of the key physiological wound healing processes.

We present four cases in which Copper Dressings were used throughout the wound healing process, until complete wound closure. The wounds were of different aetiologies, infected and non-infected, with variable amounts of granulation tissue in patients with and without diabetes.

The study demonstrates that Copper Dressings are compatible with all stages of wound healing, making them a continuous and comprehensive wound management and treatment approach. By using Copper Dressings throughout the healing process, wound care becomes more efficient, convenient, and comfortable for both patients and health professionals. The findings presented in this study highlight the transformative potential of copper-impregnated wound dressings in wound care.

Their efficacy across different wound types and aetiologies, such as diabetic ulcers, vascular insufficiency, and surgical wounds, reinforces their role as a valuable therapeutic option. Embracing Copper Dressings can lead to improved patient outcomes, reduced healthcare costs, and, ultimately, a better quality of life for patients affected by hard-to-heal wounds.

'The results demonstrate the potential of Copper Dressings to be an important weapon in the arsenal of hard-to-heal wound management. Our findings support the concept of 'continuum of care' (COC) of Copper Dressings to serve as an effective and holistic dressing for wound care treatment.

Melamed, Eyal, and Borkow, Gadi. "Continuum of care in hard-to-heal wounds by copper dressings: a case series." *Journal of Wound Care* 32.12 (2023): 788-796.
Read the full text online: <https://doi.org/10.12968/jowc.2023.32.12.788>

Continuum of Care in Hard to Heal Wounds by Copper Dressings

Eyal Melamed¹ and Gadi Borkow^{2,3}

¹Foot and Ankle Service, Department of Orthopaedics, Rambam Health Care Campus, Haifa 3109601, Israel, e_melamed@rambam.health.gov.il; ²The Skin research institute, The Dead-Sea & Arava Science Center, Masada 8693500, Israel; and ³MedCu Technologies Ltd., Herzliya 4672200, Israel, gadib@medcu.com

To access the final edited and published work see: <https://doi.org/10.12968/jowc.2023.32.12.788>

Abstract

The quest for an ideal wound dressing has been a longstanding challenge due to the complex nature of wound healing, including stages of hemostasis, inflammation, maturation, and remodeling, with overlapping timelines. This makes it difficult to find a single dressing that optimally supports all phases of wound healing. In addition, the ideal wound dressing should possess antibacterial properties and be capable of effectively debriding and lysing necrotic tissue. Copper is an essential trace element that participates in many of the key physiological wound healing processes. Copper stimulates excretion of various cytokines and growth factors, thus promoting angiogenesis, granulation tissue formation, extracellular matrix proteins secretion, and epithelization. Harnessing this knowledge, we have utilized copper oxide impregnated wound dressings in numerous cases and observed their remarkable benefits throughout the entire wound healing process. This led us to postulate the 'continuum of care' hypothesis of copper dressings. In this paper we describe 4 cases of hard-to-heal wounds of various etiologies, in which we applied copper dressings consistently across all stages of wound healing, with rapid uneventful healing, thus successfully implementing the continuum of care principle.

Keywords: Copper oxide, Wound Dressings, Wound Healing, Angiogenesis, Extracellular Matrix, Chronic Wounds.

Introduction

Hard-to-heal and chronic wounds are a significant medical challenge that can have a profound impact on patients' quality of life, with severe emotional and physical stress. These wounds reduce patients' physical activity and even social connections .1 They create a significant financial burden on the patients and healthcare system. Chronic wounds may never heal or may take years to do so. They are associated with high morbidity and mortality due to tissue inflammation and infection.2 These wounds, which fail to progress through the normal healing stages in a timely manner, leading to persistent inflammation, are usually associated with systemic pathologies, such as diabetes, atherosclerosis and microangiopathic disease that result in ischemia,3, 4 chronic venous insufficiency,5 vasculitis6 and in pressure injuries, necrosis of the integument.7 Common types of hard-to-heal wounds include diabetic foot ulcers, venous leg ulcers, pressure injuries (bedsores), and non-healing surgical wounds.

Wound healing, following damage to the skin barrier, is a finely balanced, complex but efficient process traditionally described as comprising three overlapping and coordinated cellular and molecular events that occur immediately after hemostasis is achieved: inflammation, proliferation and remodeling.8-11 These orchestrated events are stimulated and controlled by multiple secreted factors by the epidermal, dermal, endothelial and immune cells, and involve numerous processes such as cell proliferation, migration and differentiation, and formation of the extracellular matrix that gives the strength and elasticity to the forming new skin. Disruption of one or several of coordinated events may lead to delayed wound closure, wound healing defects, such as excessive scar tissue and wound chronicity.12

The secreted factors include vascular endothelial cell growth factor (VEGF), transforming growth factor (TGF)- β , platelet-derived growth factor (PDGF), matrix metalloproteinases (MMPs), Heat shock protein-47 (HSP-47) and fibroblast growth factor (FGF). VEGF is considered a key signal that stimulates angiogenesis and regulates scar tissue production during the early and late stages of the wound healing, respectively.¹³ TGF β is involved in all phases of the wound healing by regulating cell proliferation, differentiation, production and secretion of extracellular matrix (ECM) proteins, modulation of the immune response, and plays a key role in scar formation.¹⁴⁻¹⁷ PDGF stimulates proliferation and novel gene expression in monocytes-macrophages and fibroblasts.¹⁸ MMPs are the major group of proteases involved in the autolytic debridement and remodeling of the extracellular matrix (ECM).^{19, 20} Dermal fibroblasts secrete ECM proteins, such as collagen and elastin, which are crosslinked by Lysyl oxidase (LOX).²¹⁻²³ HSP-47, a collagen-specific chaperone, is needed for the formation of the collagen triple helical structure.²⁴ Once formed, the ECM gives support, strength and elasticity to the growing tissue. FGF stimulate angiogenesis, proliferation of fibroblasts and reduced scar formation.²⁵

In injured skin, many of the finely balanced wound healing repair mechanisms are dependent on their interaction with copper.² Copper stimulates angiogenesis²⁶⁻²⁸ by inducing generation of VEGF by keratinocytes during the inflammatory phase.²⁹ PDGF-stimulated vascular smooth cell migration, essential after vascular damage, is copper-dependent.³⁰ Proliferation of dermal fibroblasts²⁰ and the secretion of collagens (types I, II, and V), HSP-47 and elastin fiber components (elastin, fibrillins) by the fibroblasts is stimulated by copper during the proliferation and remodeling phases.^{26, 31, 32} LOX, needed for efficient ECM protein cross-linking between elastin and collagen, requires copper to function.²³ The expression of MMP-1, a key autolytic protease released by the granulation tissue, is stimulated by copper.²⁰ MMP-1 is involved in the autolytic debridement of the dead tissues and is involved in the remodeling of the ECM. Copper is also involved in the modulation of integrins by differentiated keratinocytes during the remodeling phase.³³ The

capacity of copper to enhance faster closure of full-thickness wounds was demonstrated in several wound animal models,³⁴⁻³⁶ including in diabetic mice.³⁷ In accordance, copper chelation delays wound closure ³⁴.

Infections of the wound may cause wound deterioration, delay wound healing, and even cause wound chronicity.³⁸ Biofilm usually is found in chronic wounds, conferring protection to the underlying bacteria from the host defenses and antibiotics.³⁸ The presence of bacteria in the wound, even at low amounts, may result in consistent and high induction of inflammatory mediators, metabolic wastes and toxins, hypoxia and production of debilitated renewed skin tissues.³⁹⁻⁴¹ Thus, reducing the microbial contamination of wounds increases the capacity of the wound to heal.

Copper has intrinsic biocidal properties.⁴² Tolerant microbes to copper are extremely rare. This lack of resistance to copper is explained by the capacity of copper to damage in parallel in a non-specific manner many key factors of the micro-organisms.⁴² Copper oxide impregnated wound dressings, hereafter called COD, possess potent antimicrobial properties.⁴³ These dressings have been cleared by the USA FDA, EU and other regulatory bodies for the management of acute and chronic wounds, such as diabetic ulcers, pressure injuries, and venous ulcers. The COD are soft, single use sterile wound dressings composed of a highly absorbent layer and one or two non-binding layers. All layers are impregnated with copper oxide microparticles that serve as a reservoir of copper ions that are slowly and constantly liberated in the presence of moisture at ppm levels.⁴⁴ The non-binding layer(s) is placed directly in contact with the wound bed. The wound dressings are provided with or without an adhesive contour (Figure 1). The non-adhesive wound dressings can be cut, trimmed or fold over according to the size and shape of the wound. The dressings can be used up to 7 days or until they are completely soaked with wound exudate.⁴⁵




Figure 1. The copper oxide impregnated wound dressings are provide with (a) or without (b) an adhesive contour. They are composed of 2 (c) or 3 (d) layers. The orange layer is a non-adherent layer that is placed directly in contact with the wound bed. The beige layer is a highly absorbent layer that can absorb ~10 times its weight. The 3-layer dressing is more appropriate for deep cavities and tunnels.

We present 4 cases in which the COD were used throughout the wound healing process, until complete wound closure. The wounds were of different etiologies, infected and non-infected with variable amount of granulation tissue in diabetics and non-diabetic patients. The results demonstrate the potential of COD to be an important weapon in the arsenal of chronic and hard-to-heal wounds ~~management of chronic ulcers~~ (COD) of copper dressings to serve as an effective and holistic wound dressing for wound treatment.

Case 1: Healing of ray amputation in a diabetic vasculopathic patient on hemodialysis

An 82-year-old man with Non-Insulin-Dependent Diabetes Mellitus (NIDDM) and End-Stage Renal Disease (ESRD) undergoing dialysis was admitted to the hospital due to gangrene of the 3rd toe and ischemia of the 4th toe, accompanied by cellulitis of the right foot (Figure 2A and B). The patient had peripheral vascular disease (PVD) with intermittent claudication and no detectable pulses distal to the femoral artery. Attempted angiography was unsuccessful due to the presence of hard calcifications in the arteries that prevented the passage of the catheter (Figures 2C and D).

Subsequently, a femoral-popliteal bypass surgery was performed, which resulted in successful improvement of blood flow and temperature to the midfoot level. During the same surgery, the 3rd and 4th rays were amputated (Figure 2E).

Following the surgery, the amputation wound was treated with antibiotics and a twice-daily chlorine-based solution to promote healing and prevent infection, but it still showed signs of ischemia (Figure 2F). On the 9th day after the surgery, antibiotic treatment was discontinued, and application of COD wound management was initiated (Figures 2G). Over the next one to two weeks, there was noticeable progression of granulation tissue in the wound (Figure 2H). However, a significant portion of the wound remained filled with necrotic tissue, and attempts at bedside debridement (Figure 2I) resulted in only minor improvement (Figure 2K). Wound management with COD was continued, further progression of wound healing was observed (Figures 2L and 2M), with 100% red granulation at two months (Figure 2N) and full

epithelization (wound closure) at three months (Figures 2O and 2P). In this case the continuum of care (COC) is exemplified by COD's antibacterial efficacy and debridement, granulation tissue formation, and epithelization stimulating activities.

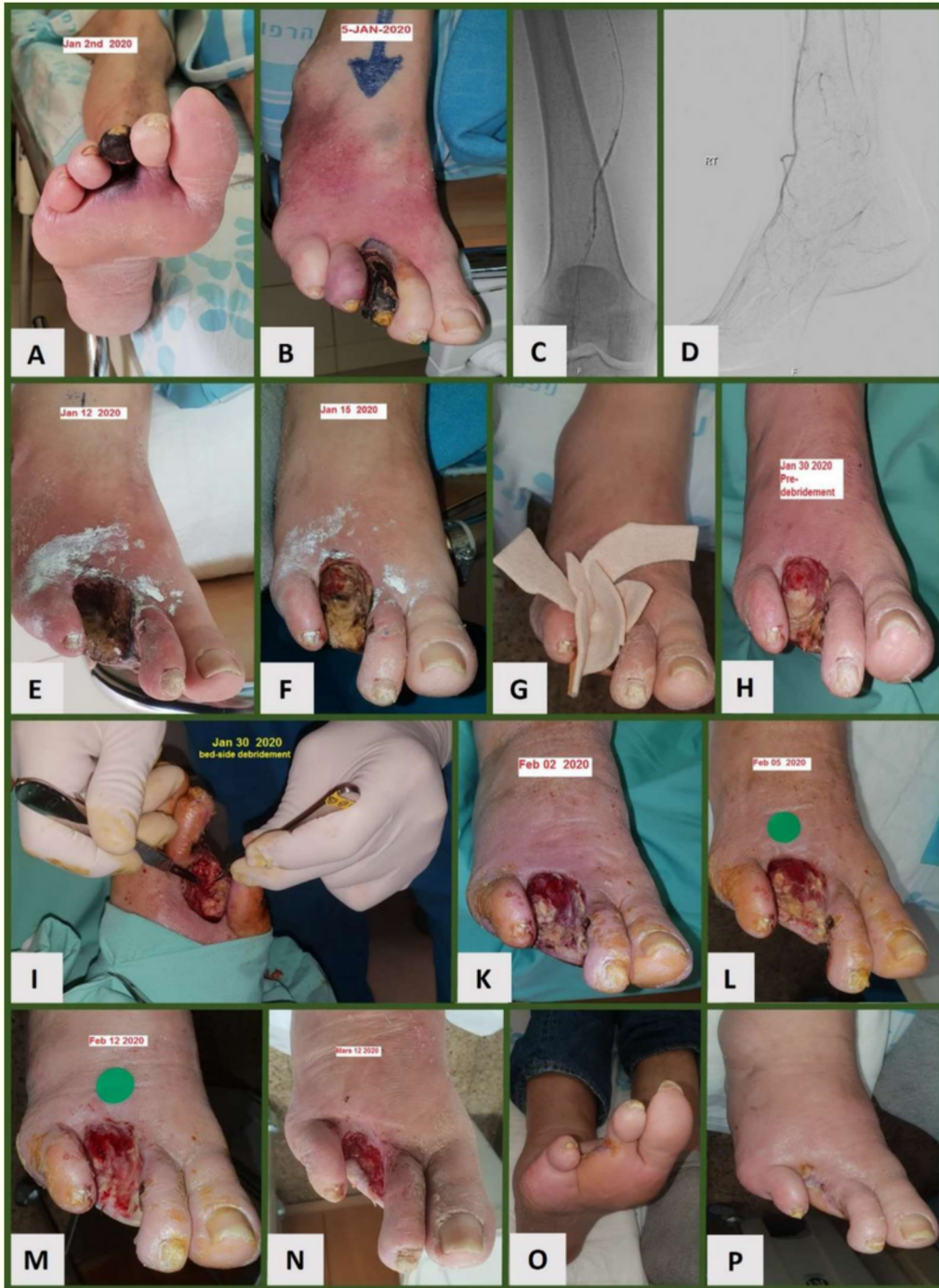

Figure 2. Healing of ray amputation in a diabetic vasculopathic patient on hemodialysis.

Case 2: Healing of trans-metatarsal amputation stump with large exposed bone— near full-coverage with normal skin

A 46-year-old patient with NIDDM and neuropathy underwent a trans-metatarsal amputation in February 2020. The wound dehisced, showing abundant necrotic tissue, but no signs of infection were observed (Figure 3A). Due to the COVID-19 pandemic, the patient was discharged home and could only return for further treatment after 2.5 months, in May 2020, once the COVID-19 lockdown was lifted. At this point, the wound remained open with necrotic margins and revealed a prominent bone (Figure 3B).

A debridement of the skin and soft tissue was performed, and the prominent bone was trimmed (Figure 3C). COD was applied for six days on the wound, even on top of the exposed bone. Upon the first COD dressing removal, the wound showed no signs of infection (Figure 3D), and the trimmed bone was covered with a thin layer of granulation tissue. The application of COD was continued once weekly, and over time, the wound gradually filled with granulation tissue, eventually being covered with healthy, creeping skin and epithelium (Figures 3E-G). After five months of COD treatment, the wound was successfully closed (Figure 3H). To promote skin maturation, COD was still applied to the closed wound for a few more months. At the three-year follow-up, the wound remained stably closed (Figure 3I). In this case the COC approach includes the antibacterial activity of COD as well as intense granulation tissue formation, significant epithelization and skin maturation.

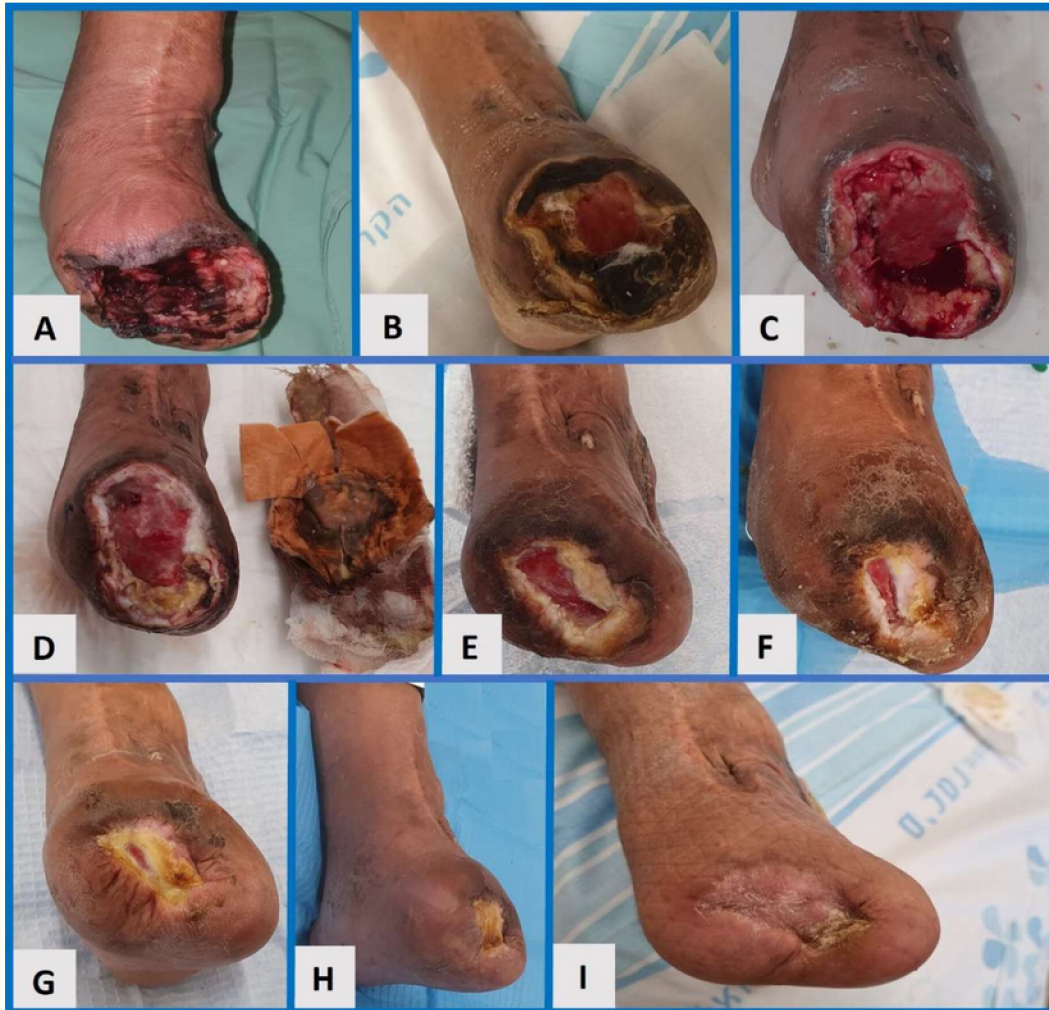

Figure 3: Healing and full closure of trans-metatarsal amputation stamp with large exposed bone.

Case 3: Healing of pressure injury after partial calcaneotomy

An 89-year-old man developed a pressure injury with necrosis of the Achilles Tendons insertion to the heel (Figure 4A) while recovering in bed after having hip fracture fixation. A wide debridement and partial calcaneotomy were performed leaving a large wound measuring approximately 5x10x2.5 cm (Figure 4B). The wound was treated with COD, which was changed after 2 days. At that time a clot was seen in the wound but the wound looked clean (Figure 4C).

While NPWT is the typical treatment for such cases, the decision was made to continue with the COD treatment. A bilayer copper dressing was packed into the wound and a larger COD dressing covered the heel and the nearby area. Gradually granulation tissue filled the wound and skin crawled from the sides. Once the wound was stable, a more convenient adhesive COD was applied. COD were applied 1-2 times a week; granulation tissue formed, and the wound gradually decreased in size while undergoing epithelialization (Figures 4D-G). Throughout this period, the patient was mobile (Figure 4H). At 3.5 months, the wound was successfully closed (Figure 4I). Antibiotic was prescribed for only 5 days post-surgery. In this case the COC approach is expressed by antibacterial activity, granulation tissue formation, and epithelization.

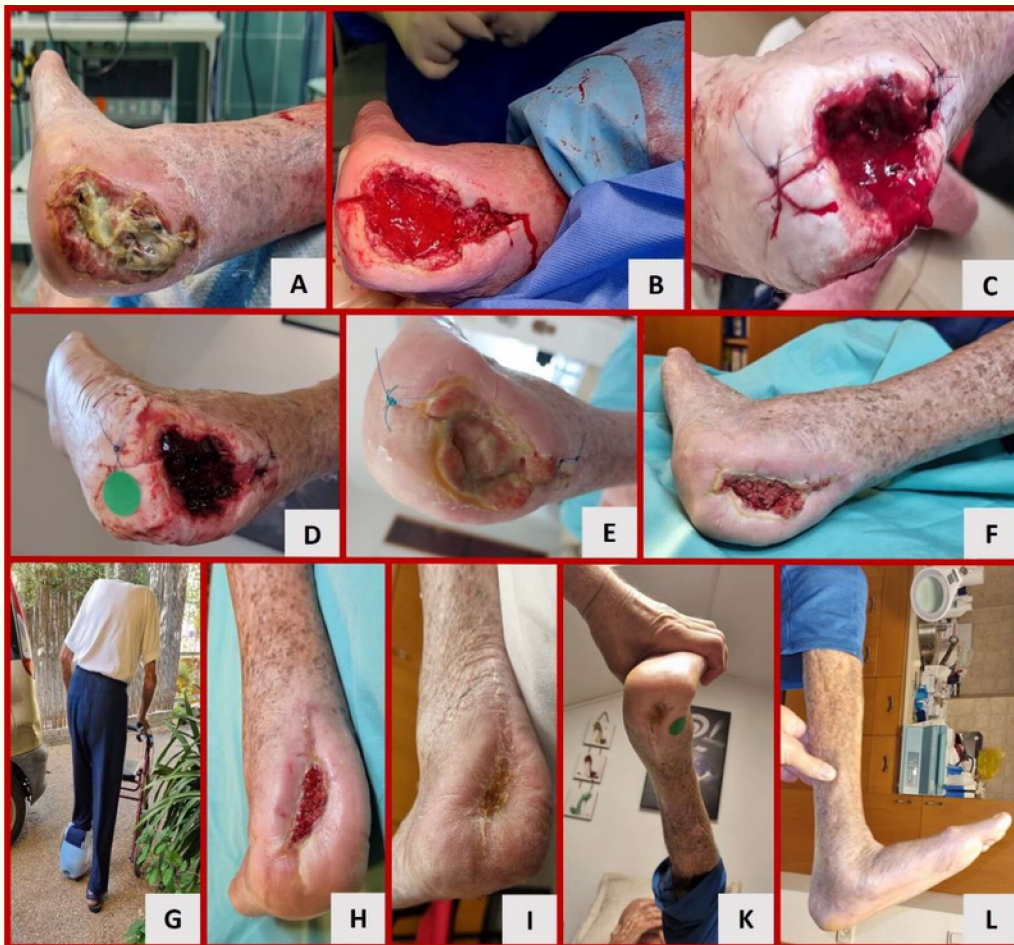

Figure 4: Healing of pressure injury after partial calcaneectomy.

Case 4: Healing of a venous harvesting site

A 68-year-old woman with diabetes was admitted to the hospital due to dehiscence and necrosis in the leg's venous harvesting site, two months after coronary artery bypass surgery. She also had osteomyelitis of the sternum, requiring six weeks of antibiotic treatment. The 36 cm² leg wound (measured by Tissue Analytics software) exhibited abundant necrotic and fibrous tissue, with surrounding redness indicating possible inflammation or infection (Figure 5A). After one week of COD treatment (and concomitant antibiotic treatment due to the sternal osteomyelitis), the surrounding redness significantly improved, and most of the black necrotic tissue was gone (Figure 5B). Over the course of four weeks, the wound filled with red granulation tissue (Figure 5C). Subsequently, epithelium advanced from the wound edges (Figure 5D), and by the fifth month, the wound was successfully closed (Figure 5E). COD application was continued for two more months to encourage skin maturation. After a year of COD management, the leg and wound area showed near-normal appearance (Figure 5F). In this case the COD approach encompassed antibacterial activity, debridement, granulation tissue formation, and epithelization.

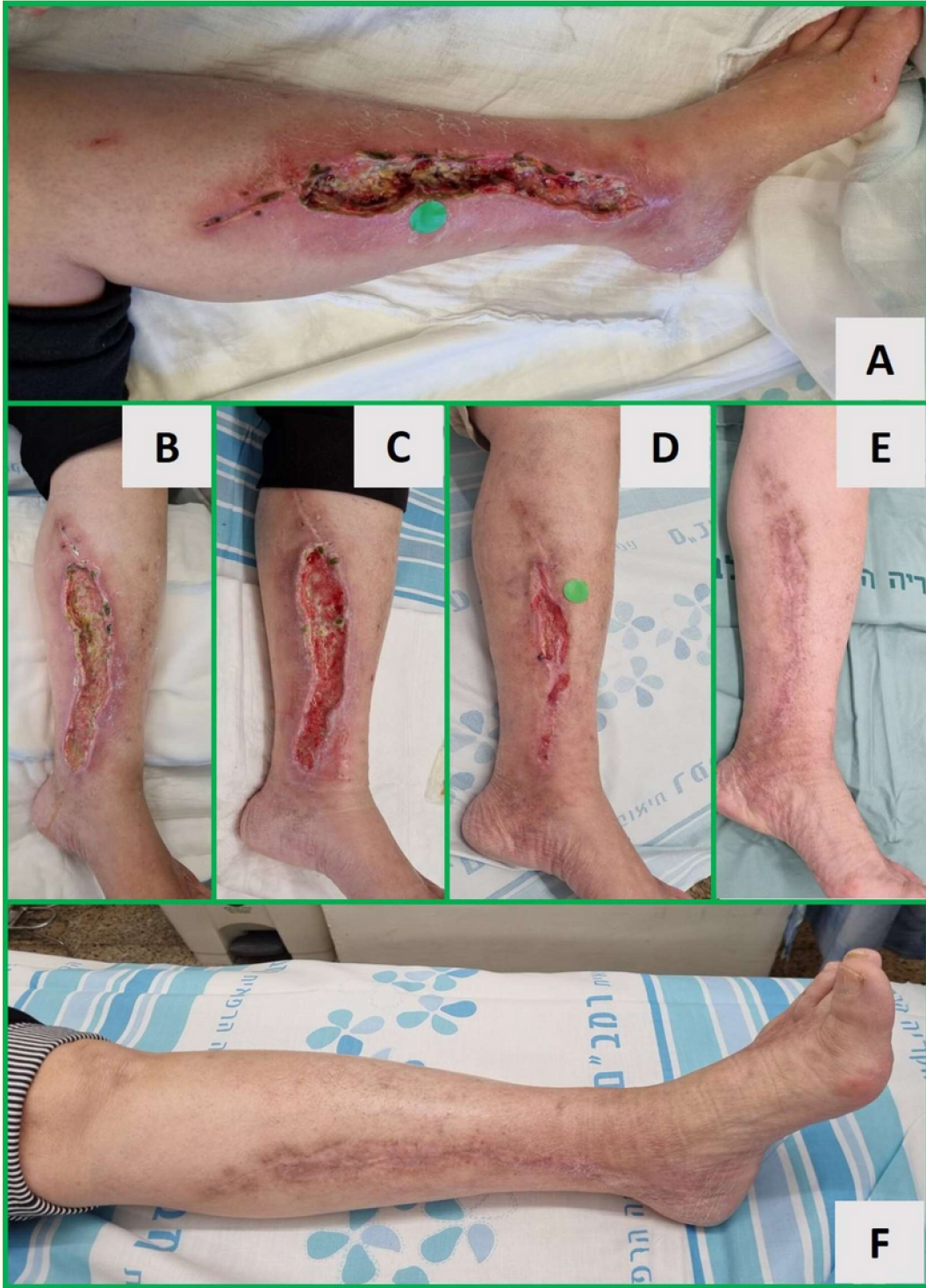

Figure 5: Healing of a venous harvesting site.

Discussion

Chronic wound management poses a significant challenge for treating physicians due to the intricate causes and symptoms associated with the healing process. Each step of chronic wound healing necessitates a distinct intervention or solution, complicating the current management for therapists seeking the most appropriate treatment modality. There are currently over 800 FDA cleared products, including wound dressings, “for the management of wounds so that the natural healing process can take place” (K. Dev Ve rma, MD, Division of Dermatology and Dentistry, CDER, FDA; Wound Healing Workshop, April 28, 2022 <https://www.fda.gov/media/167141/download>).

Numerous methods have been proposed to treat chronic wounds, targeting different stages in the wound healing process.¹¹ These methods include Negative Pressure Wound Therapy (NPWT), Hyperbaric Oxygen Therapy, stem cell therapies, skin grafting, skin substitutes, and antimicrobial dressings. Wound care modalities often are classified as antibacterial, necrolytic (debriding), those which encourage granulation tissue formation, and those which act as skin substitutes. They usually affect one or two of the healing phases, hence the need to decide when and with what to replace them. In addition, they come with other drawbacks, including their high cost, complexity, and the need for specialized trained personnel. In developed countries, they impose a significant burden on the healthcare system, while in developing countries, they are often unaffordable.

There is a pressing need for an effective innovation that simplifies the management of chronic wounds throughout the entire healing process, regardless of healing status. A solution is required that can be easily continued from the initial skin rupture to wound closure without relying on costly or intricate procedures. Such an innovation would have a transformative impact on chronic wound management and significantly alleviate the burden on healthcare systems globally. This may be of significant impact in developing countries, where wound clinics and personnel trained to manage chronic wounds is lacking.

Copper is an essential nutrient for humans involved in many of the physiological processes in all body tissues.^{46, 47} In non-injured skin, copper serves as a cofactor of superoxide dismutase, an antioxidant enzyme important for protection against free radicals;^{48, 49} as a cofactor of tyrosinase, a melanin biosynthesis essential enzyme responsible for skin and hair pigmentation^{50, 51} and inhibits membrane damage and lipid peroxidation.⁵² Copper can cross the stratum corneum and be absorbed to a certain extent through the skin.^{53, 54} Increased pro-collagen 1, elastin, and TGF-beta1 expression by copper ions of intact skin was demonstrated by using ex-vivo human skin explants.³¹ Accordingly, copper containing cosmetic products that reduce skin wrinkles⁵⁵ and improve the well-being of the skin^{56, 57} are in use, e.g. cosmetic pillowcases, diapers and socks.⁵⁸⁻⁶⁰

Recent advancements have shown that copper oxide wound dressings (COD) have a significant positive impact on wound healing.^{37, 44, 45, 61-64} COD demonstrated their efficacy in protecting against microbial infections, promoting autolytic debridement, facilitating granulation tissue formation, and enhancing epithelization and skin maturation after wound closure.^{44, 61, 63, 64} In a recent clinical trial conducted with diabetic patients, who suffered from stagnated indolent wounds despite standard of care, dramatically improved during one month of COD application.⁶¹ Similarly, the improvements of different hard-to-heal wounds, of patients with different etiologies, were also recently described.^{44, 63} The capacity and the molecular mechanisms by which COD directly enhance wound healing, not-related to their antimicrobial properties, was demonstrated in a murine diabetic model.⁶⁵

Conclusions

This article presents four representative cases of challenging wounds treated with COD, demonstrating its effectiveness in their continuum of care of the wounds under diverse clinical conditions, including diabetes, PVD, ESRD, and old age. The presented cases are skin necrosis due to ischemia of the toes accompanied by cellulitis; large exposed bone after trans-metatarsal amputation, wound necrosis after venous harvesting for cardiac bypass surgery and big heel void

after partial calcanectomy for pressure injury. COD were consistently applied from the initial stages of the wounds to the post-closure period, effectively replacing traditional NPWT and skin grafting. The use of COD resulted in favorable functional outcomes, improved skin quality, and reduced scarring, all at a significant lower cost. These results align with previous basic science research on the effect of copper on wound healing^{31, 37, 43, 52, 62, 66} and underscore the versatile applications of COD.

The study demonstrates that COD is compatible with all stages of wound healing, making it a continuous and comprehensive wound management and treatment approach. By utilizing COD throughout the healing process, wound care becomes more efficient, convenient, and comfortable for both patients and healthcare professionals. The findings presented in this study highlight the transformative potential of copper oxide impregnated wound dressings in wound care. Its efficacy across different wound types and etiologies, such as diabetic ulcers, vascular insufficiency, and surgical wounds, reinforces its role as a valuable therapeutic option. Embracing COD can lead to improved patient outcomes, reduced healthcare costs, and ultimately, better quality of life for those affected by hard-to-heal wounds. Further research and integration into clinical practice will solidify COD's position as a groundbreaking advancement in wound care.

References

1. Goodridge D, Trepman E, Sloan J et al. Quality of life of adults with unhealed and healed diabetic foot ulcers. *Foot and Ankle International* 2006;27(4): 274-80. DOI: [10.1177/107110070602700408](https://doi.org/10.1177/107110070602700408)
2. Kornblatt AP, Nicoletti VG, Travaglia A. The neglected role of copper ions in wound healing. *J Inorg Biochem* 2016;161: 1-8. DOI: [10.1016/j.jinorgbio.2016.02.012](https://doi.org/10.1016/j.jinorgbio.2016.02.012)
3. Ferreira MC, Tuma P, Jr., Carvalho VF, Kamamoto F. Complex wounds. *Clinics* 2006;61(6): 571-8. DOI: [10.1590/s1807-59322006000600014](https://doi.org/10.1590/s1807-59322006000600014)
4. Bowering CK. Diabetic foot ulcers. Pathophysiology, assessment, and therapy. *Can Fam Physician* 2001;47: 1007-16.
5. Abbade LP, Lastoria S. Venous ulcer: epidemiology, physiopathology, diagnosis and treatment. *Int J Dermatol* 2005;44(6): 449-56. DOI: [10.1111/j.1365-4632.2004.02456.x](https://doi.org/10.1111/j.1365-4632.2004.02456.x)
6. Coelho S, Amarelo M, Ryan S, Reddy M, Sibbald RG. Rheumatoid arthritis-associated inflammatory leg ulcers: a new treatment for recalcitrant wounds. *Int Wound J* 2004;1(1): 81-4. DOI: [10.1111/j.1742-481x.2004.0002.x](https://doi.org/10.1111/j.1742-481x.2004.0002.x)
7. Cullum N, Nelson EA, Nixon J. Pressure ulcers. *Clin Evid* 2006(15): 2592-606.
8. Richardson M. Acute wounds: an overview of the physiological healing process. *Nurs Times* 2004;100(4): 50-3.
9. Diegelmann RF, Evans MC. Wound healing: an overview of acute, fibrotic and delayed healing. *Front Biosci* 2004;9: 283-9. DOI: [10.2741/1184](https://doi.org/10.2741/1184)
10. Childs DR, Murthy AS. Overview of Wound Healing and Management. *Surg Clin North Am* 2017;97(1): 189-207. DOI: [10.1016/j.suc.2016.08.013](https://doi.org/10.1016/j.suc.2016.08.013)
11. Baron JM, Glatz M, Proksch E. Optimal Support of Wound Healing: New Insights. *Dermatology* 2020;236(6): 593-600. DOI: [10.1159/000505291](https://doi.org/10.1159/000505291)
12. Landen NX, Li D, Stahle M. Transition from inflammation to proliferation: a critical step during wound healing. *Cell Mol Life Sci* 2016;73(20): 3861-85. DOI: [10.1007/s00018-016-2268-0](https://doi.org/10.1007/s00018-016-2268-0)
13. ~~Wilgus TA. Vascular Endothelial Growth Factor and Cutaneous Scarring. *Adv Wound Care (New Rochelle)* 2019;8(12): 671-8. DOI: [10.1089/wound.2018.0796](https://doi.org/10.1089/wound.2018.0796)~~
14. ~~Penn JW, Grobelaar AO, Rolfe KJ. The role of the TGF-beta family in wound healing, burns and scarring: a review. *Int J Burns Trauma* 2012;2(1): 18-28.~~
15. Kiritsi D, Nystrom A. The role of TGFbeta in wound healing pathologies. *Mech Ageing Dev* 2018;172: 51-8. DOI: [10.1016/j.mad.2017.11.004](https://doi.org/10.1016/j.mad.2017.11.004)
16. ~~Ramirez H, Patel SB, Pastar I. The Role of TGFbeta Signaling in Wound Epithelialization. *Adv Wound Care (New Rochelle)* 2014;3(7): 482-91. DOI: [10.1089/wound.2013.0466](https://doi.org/10.1089/wound.2013.0466)~~
17. ~~Philips N, Conte J, Chen YJ et al. Beneficial regulation of matrix metalloproteinases and their inhibitors, fibrillar collagens and transforming growth factor-beta by Polypodium leucotomos, directly or in dermal fibroblasts, ultraviolet radiated fibroblasts, and melanoma cells. *Arch Dermatol Res* 2009;301(7): 487-95. DOI: [10.1007/s00403-009-0950-x](https://doi.org/10.1007/s00403-009-0950-x)~~
18. Wong AYW, Ong BSY, Lee ARYB et al. Topical Biological Agents as Adjuncts to Improve Wound Healing in Chronic Diabetic Wounds: A Systematic Review of Clinical

- Evidence and Future Directions. *Cureus* 2022;14(7): e27180.
DOI: [10.7759/cureus.27180](https://doi.org/10.7759/cureus.27180)
19. Michopoulou A, Rousselle P. How do epidermal matrix metalloproteinases support re-epithelialization during skin healing? *Eur J Dermatol* 2015;25 Suppl 1: 33-42.
DOI: [10.1684/ejd.2015.2553](https://doi.org/10.1684/ejd.2015.2553)
20. Philips N, Hwang H, Chauhan S, Leonardi D, Gonzalez S. Stimulation of cell proliferation and expression of matrixmetalloproteinase-1 and interleukin-8 genes in dermal fibroblasts by copper. *Connect Tissue Res* 2010;51(3): 224-9.
DOI: [10.3109/03008200903288431](https://doi.org/10.3109/03008200903288431)
21. Szauter KM, Cao T, Boyd CD, Csiszar K. Lysyl oxidase in development, aging and pathologies of the skin. *Pathol Biol (Paris)* 2005;53(7): 448-56.
DOI: [10.1016/j.patbio.2004.12.033](https://doi.org/10.1016/j.patbio.2004.12.033)
22. Atsawasuwan P, Mochida Y, Katafuchi M et al. Lysyl oxidase binds transforming growth factor-beta and regulates its signaling via amine oxidase activity. *J Biol Chem* 2008;283(49): 34229-40. DOI: [10.1074/jbc.M803142200](https://doi.org/10.1074/jbc.M803142200)
23. Rucker RB, Kosonen T, Clegg MS et al. Copper, lysyl oxidase, and extracellular matrix protein cross-linking. *Am J Clin Nutr* 1998;67(5 Suppl): 996S-1002S.
DOI: [10.1093/ajcn/67.5.996S](https://doi.org/10.1093/ajcn/67.5.996S)
24. Widmer C, Gebauer JM, Brunstein E et al. Molecular basis for the action of the collagen-specific chaperone Hsp47/SERPINH1 and its structure-specific client recognition. *Proc Natl Acad Sci U S A* 2012;109(33): 13243-7.
DOI: [10.1073/pnas.1208072109](https://doi.org/10.1073/pnas.1208072109)
25. Liu Y, Liu Y, Deng J, Li W, Nie X. Fibroblast Growth Factor in Diabetic Foot Ulcer: Progress and Therapeutic Prospects. *Front Endocrinol (Lausanne)* 2021;12: 744868.
DOI: [10.3389/fendo.2021.744868](https://doi.org/10.3389/fendo.2021.744868)
26. Gerard C, Bordeleau LJ, Barralet J, Doillon CJ. The stimulation of angiogenesis and collagen deposition by copper. *Biomaterials* 2010;31(5): 824-31.
DOI: [10.1016/j.biomaterials.2009.10.009](https://doi.org/10.1016/j.biomaterials.2009.10.009)
27. Raju KS, Alessandri G, Ziche M, Gullino PM. Ceruloplasmin, copper ions, and angiogenesis. *J Natl Cancer Inst* 1982;69(5): 1183-8.
28. Parke A, Bhattacharjee P, Palmer RM, Lazarus NR. Characterization and quantification of copper sulfate-induced vascularization of the rabbit cornea. *Am J Pathol* 1988;130(1): 173-8.
29. Sen CK, Khanna S, Venojarvi M et al. Copper-induced vascular endothelial growth factor expression and wound healing. *Am J Physiol Heart Circ Physiol* 2002;282(5): H1821-H7. DOI: [10.1152/ajpheart.01015.2001](https://doi.org/10.1152/ajpheart.01015.2001)
30. Ashino T, Kohno T, Sudhahar V et al. Copper transporter ATP7A interacts with IQGAP1, a Rac1 binding scaffolding protein: role in PDGF-induced VSMC migration and vascular remodeling. *Am J Physiol Cell Physiol* 2018;315(6): C850-C62.
DOI: [10.1152/ajpcell.00230.2018](https://doi.org/10.1152/ajpcell.00230.2018)
31. Ogen-Shtern N, Chumin K, Cohen G, Borkow G. Increased pro-collagen 1, elastin, and TGF-beta1 expression by copper ions in an ex-vivo human skin model. *J Cosmet Dermatol* 2020;19(6): 1522-7. DOI: [10.1111/jocd.13186](https://doi.org/10.1111/jocd.13186)

32. Tsai CY, Finley JC, Ali SS, Patel HH, Howell SB. Copper influx transporter 1 is required for FGF, PDGF and EGF-induced MAPK signaling. *Biochem Pharmacol* 2012;84(8): 1007-13. DOI: [10.1016/j.bcp.2012.07.014](https://doi.org/10.1016/j.bcp.2012.07.014)
33. Tenaud I, Sainte-Marie I, Jumbou O, Litoux P, Dreno B. In vitro modulation of keratinocyte wound healing integrins by zinc, copper and manganese. *Br J Dermatol* 1999;140(1): 26-34. DOI: [10.1046/j.1365-2133.1999.02603.x](https://doi.org/10.1046/j.1365-2133.1999.02603.x)
34. Das A, Sudhakar V, Chen GF et al. Endothelial Antioxidant-1: a Key Mediator of Copper-dependent Wound Healing in vivo. *Sci Rep* 2016;6: 33783. DOI: [10.1038/srep33783](https://doi.org/10.1038/srep33783)
35. Kumar A, Pandit V, Nagaich U. Therapeutic evaluation of chemically synthesized copper nanoparticles to promote full-thickness excisional wound healing. *Int J Applied Pharmaceutics* 2020;12(6): 136-42.
36. Ghosh D, Godeshala S, Nitiyanandan R et al. Copper-Eluting Fibers for Enhanced Tissue Sealing and Repair. *ACS Appl Mater Interfaces* 2020;12(25): 27951-60. DOI: [10.1021/acsami.0c04755](https://doi.org/10.1021/acsami.0c04755)
37. Borkow G, Gabbay J, Dardik R et al. Molecular mechanisms of enhanced wound healing by copper oxide-impregnated dressings. *Wound Repair Regen* 2010;18(2): 266-75. DOI: [10.1111/j.1524-475X.2010.00573.x](https://doi.org/10.1111/j.1524-475X.2010.00573.x)
38. Edwards R, Harding KG. Bacteria and wound healing. *Curr Opin Infect Dis* 2004;17(2): 91-6. DOI: [10.1097/00001432-200404000-00004](https://doi.org/10.1097/00001432-200404000-00004)
39. Ovington L. Bacterial toxins and wound healing. *Ostomy Wound Manage* 2003;49(7A Suppl): 8-12.
40. Robson MC, Stenberg BD, Hegggers JP. Wound healing alterations caused by infection. *Clin Plast Surg* 1990;17(3): 485-92.
41. Laato M, Niinikoski J, Lundberg C, Gerdin B. Inflammatory reaction and blood flow in experimental wounds inoculated with *Staphylococcus aureus*. *Eur Surg Res* 1988;20(1): 33-8. DOI: [10.1159/000128738](https://doi.org/10.1159/000128738)
42. Borkow G, Gabbay J. Copper as a biocidal tool. *Curr Med Chem* 2005;12(18): 2163-75. DOI: [10.2174/0929867054637617](https://doi.org/10.2174/0929867054637617)
43. Borkow G, Roth T, Kalinkovich A. Wide spectrum potent antimicrobial efficacy of wound dressings impregnated with cuprous oxide microparticles. *Microbiology Research* 2022;13(3): 366-76. DOI: [10.3390/microbiolres13030029](https://doi.org/10.3390/microbiolres13030029)
44. Melamed E, Kiambi P, Okoth D et al. Healing of Chronic Wounds by Copper Oxide-Impregnated Wound Dressings-Case Series. *Medicina (Kaunas)* 2021;57(3): 296. DOI: [10.3390/medicina57030296](https://doi.org/10.3390/medicina57030296)
45. Borkow G, Melamed E. Copper, an abandoned player returning to the wound healing battle. In: Shahin A, editor. *Recent Advances in Wound Healing*. 1st ed. London: IntechOpen; 2021. DOI: [10.5772/intechopen.96952](https://doi.org/10.5772/intechopen.96952)
46. Uauy R, Olivares M, Gonzalez M. Essentiality of copper in humans. *Am J Clin Nutr* 1998;67(5 Suppl): 952S-9S. DOI: [10.1093/ajcn/67.5.952S](https://doi.org/10.1093/ajcn/67.5.952S)
47. Vetchy MPJV. Biological role of copper as an essential trace element in the human organism. *Ceska Slov Farm* 2018;67(4): 143-53.
48. Kobayashi T, Saito N, Takemori N et al. Ultrastructural localization of superoxide dismutase in human skin. *Acta Derm Venereol* 1993;73(1): 41-5. DOI: [10.2340/00015555734145](https://doi.org/10.2340/00015555734145)

49. Sheng Y, Abreu IA, Cabelli DE et al. Superoxide dismutases and superoxide reductases. *Chem Rev* 2014;114(7): 3854-918. DOI: [10.1021/cr4005296](https://doi.org/10.1021/cr4005296)
50. Olivares C, Solano F. New insights into the active site structure and catalytic mechanism of tyrosinase and its related proteins. *Pigment Cell Melanoma Res* 2009;22(6): 750-60. DOI: [10.1111/j.1755-148X.2009.00636.x](https://doi.org/10.1111/j.1755-148X.2009.00636.x)
51. Hearing VJ, Jimenez M. Mammalian tyrosinase--the critical regulatory control point in melanocyte pigmentation. *Int J Biochem* 1987;19(12): 1141-7. DOI: [10.1016/0020-711x\(87\)90095-4](https://doi.org/10.1016/0020-711x(87)90095-4)
52. Phillips N, Samuel P, Parakandi H et al. Beneficial regulation of fibrillar collagens, heat shock protein-47, elastin fiber components, transforming growth factor-beta1, vascular endothelial growth factor and oxidative stress effects by copper in dermal fibroblasts. *Connect Tissue Res* 2012;53(5): 373-8. DOI: [10.3109/03008207.2012.665970](https://doi.org/10.3109/03008207.2012.665970)
53. Gorter RW, Butorac M, Cobian EP. Examination of the cutaneous absorption of copper after the use of copper-containing ointments. *Am J Ther* 2004;11(6): 453-8. DOI: [10.1097/01.mjt.0000127148.83065.e5](https://doi.org/10.1097/01.mjt.0000127148.83065.e5)
54. Hostynek JJ, Dreher F, Maibach HI. Human stratum corneum penetration by copper: in vivo study after occlusive and semi-occlusive application of the metal as powder. *Food Chem Toxicol* 2006;44(9): 1539-43. DOI: [10.1016/j.fct.2006.04.003](https://doi.org/10.1016/j.fct.2006.04.003)
55. Baek JH, Yoo MA, Koh JS, Borkow G. Reduction of facial wrinkles depth by sleeping on copper oxide-containing pillowcases: a double blind, placebo controlled, parallel, randomized clinical study. *J Cosmet Dermatol* 2012;11(3): 193-200. DOI: [10.1111/j.1473-2165.2012.00624.x](https://doi.org/10.1111/j.1473-2165.2012.00624.x)
56. Borkow G. Protection of Soldiers' feet by copper oxide impregnated socks. *Advances in Military Technology* 2013;8(2): 101-8. DOI: [10.3849/aimt.01009](https://doi.org/10.3849/aimt.01009)
57. Weinberg I, Lazary A, Jefidoff A et al. Safety of using diapers containing copper oxide in chronic care elderly patients. *The Open Biology Journal* 2013;6: 54-9. DOI: [10.2174/1874196701306010001](https://doi.org/10.2174/1874196701306010001)
58. Borkow G, Zatcoff RC, Gabbay J. Reducing the risk of skin pathologies in diabetics by using copper impregnated socks. *Med Hypotheses* 2009;73: 883-6. DOI: [10.1016/j.mehy.2009.02.050](https://doi.org/10.1016/j.mehy.2009.02.050)
59. Borkow G, Mellibovsky JC. Resolution of skin maladies of the trapped Chilean miners: the unplanned underground copper-impregnated antifungal socks "trial". *Arch Dermatol* 2012;148(1): 134-6. DOI: [10.1001/archdermatol.2011.1280](https://doi.org/10.1001/archdermatol.2011.1280)
60. Borkow G. Using Copper to Improve the Well-Being of the Skin. *Curr Chem Biol* 2014;8(2): 89-102. DOI: [10.2174/2212796809666150227223857](https://doi.org/10.2174/2212796809666150227223857)
61. Melamed E, Rovitsky A, Roth T, Assa L, Borkow G. Stimulation of Healing of Non-Infected Stagnated Diabetic Wounds by Copper Oxide-Impregnated Wound Dressings. *Medicina (Kaunas)* 2021;57(10): 1129. DOI: [10.3390/medicina57101129](https://doi.org/10.3390/medicina57101129)
62. Ogen-Shtern N, Chumin K, Silberstein E, Borkow G. Copper Ions Ameliorated Thermal Burn-Induced Damage in ex vivo Human Skin Organ Culture. *Skin Pharmacol Physiol* 2021;34(6): 317-27. DOI: [10.1159/000517194](https://doi.org/10.1159/000517194)
63. Weitman CC, Roth T, Borkow G. Copper dressings to the wound rescue after everything else failed: case report. *Arch Clin Med Case Rep* 2022;6(3): 466-73.

64. Melamed E, Rovitsky A, Roth T, Borkow G. Anterior ankle full thickness skin necrosis treated with copper oxide dressings without debridement and skin graft a case report. *Arch Clin Med Case Rep* 1980;6: 501-10.
65. Scherer SS, Pietramaggiore G, Mathews JC et al. Wound healing kinetics of the genetically diabetic mice. *Wounds* 2008;20(1): 18-28.
66. Borkow G, Okon-Levy N, Gabbay J. Copper oxide impregnated wound dressings: biocidal and safety studies. *Wounds* 2010;22: 310-6.

Informed Consent Statement: Informed consent was obtained from all subjects involved in the study.

Ethics statement: We confirm that the Committee on Publication Ethics (COPE) guidelines on good publication practice were adhered to, and in accordance to the Declaration of Helsinki.

Conflicts of Interest: E.M. is a medical consultant of MedCu Technologies. G.B. is the Chief Scientist of MedCu Technologies. The copper impregnated dressings are manufactured by MedCu Technologies.

Note: This document is the Accepted Manuscript version of a Published Work that appeared in final form in *JWC*, copyright © MA Healthcare, after peer review and technical editing by the publisher. To access the final edited and published work see [<https://doi.org/10.12968/jowc.2023.32.12.788>].