

The Journey of Copper-Impregnated Dressings in Wound Healing: From a Medical Hypothesis to Clinical Practice

Published 2025



This review follows the evolution of copper-impregnated dressings from an initial hypothesis about copper deficiency in chronic wounds to laboratory validation and clinical success. By delivering copper ions directly to the wound, these dressings provide antimicrobial protection while actively stimulating healing, offering a breakthrough in chronic wound care.

Chronic wounds are a growing global health issue, often linked to diabetes, vascular disease, and aging. Healing processes like angiogenesis, collagen production, and epithelialization depend on copper. The authors proposed that low copper levels at wound sites contribute to stalled healing.

Copper oxide dressings designed for controlled continued copper ion release were developed. In preclinical studies, these dressings accelerated wound closure, boosted angiogenesis, and improved tissue regeneration compared to silver and control dressings. Gene expression analysis showed increased levels of key factors like VEGF and HIF-1 α .

Clinical case studies and trials further confirmed the effectiveness of copper dressings across a range of hard-to-heal wounds, including diabetic foot ulcers, venous ulcers, pressure sores, necrotic wounds, and post-surgical wounds.

Additionally, copper dressings proved to be as effective as negative pressure wound therapy (NPWT), while being more cost-effective and easier to use.

The article emphasizes that copper dressings contribute to a "Continuum of Care" throughout all wound healing stages, from initial injury to complete closure, addressing infection control, inflammation reduction, granulation, epithelialization, and scar minimization.

"We envisioned that incorporating copper into wound dressings could not only minimize the risk of wound and dressing contamination, similar to silver, but also actively promote faster wound healing. This effect would be achieved through the controlled release of copper from the dressings directly into the wound site, stimulating angiogenesis and facilitating skin regeneration."

Borkow, G., & Melamed, E. (2025). The Journey of Copper-Impregnated Dressings in Wound Healing: From a Medical Hypothesis to Clinical Practice. *Biomedicines*, 13(3), 562.

Read the full text online:

<https://doi.org/10.3390/biomedicines13030562>

Review

The Journey of Copper-Impregnated Dressings in Wound Healing: From a Medical Hypothesis to Clinical Practice

Gadi Borkow^{1,2,*}  and Eyal Melamed^{3,*}¹ MedCu Technologies Ltd., Herzliya 4672200, Israel² The Skin Research Institute, The Dead-Sea & Arava Science Center, Masada 8691000, Israel³ Foot and Ankle Service, Department of Orthopedics, Bnai Zion Medical Center, Haifa 3109601, Israel

* Correspondence: gadib@medcu.com (G.B.); eyalfoot@gmail.com (E.M.)

Abstract: Background/Objectives. Chronic wounds pose a substantial global healthcare burden exacerbated by aging populations and the increasing prevalence of conditions such as diabetes, peripheral vascular disease, and venous insufficiency. Impaired physiological repair mechanisms, including angiogenesis, collagen synthesis, and re-epithelialization, hinder the healing process in chronic wounds. Many of these physiological processes are dependent on their interaction with copper. We hypothesized that the targeted delivery of copper ions to the wound bed would enhance healing. **Methods.** Wound dressings impregnated with copper oxide microparticles were designed to ensure the controlled release of copper ions. The efficacy of these dressings was evaluated using non-infected wound models, including diabetic mouse models compared against control and silver dressings. Outcome measures included wound closure rates, epidermal skin quality assessed by histopathological examination, and gene expression profiling. Clinical applications were assessed through diverse case studies and controlled trials involving chronic wound management. **Results.** Copper dressings significantly accelerated wound closure and enhanced angiogenesis compared to control and silver dressings. Histopathological analyses revealed faster granulation tissue formation, epidermal regeneration, and neovascularization. Gene expression studies showed upregulation of critical angiogenic factors such as VEGF and HIF-1 α . Investigations and clinical observations corroborated improved healing across various chronic wound types, including non-infected wounds. **Conclusions.** Copper is essential for wound healing, and copper-impregnated dressings provide a promising solution for chronic wound management. By enhancing angiogenesis and tissue regeneration, these dressings go beyond antimicrobial action, offering a cost-effective and innovative alternative to conventional therapies. Copper dressings represent a transformative advancement in addressing the challenges of chronic wound care.



Academic Editor: Julian-Dario Rembe

Received: 15 January 2025

Revised: 9 February 2025

Accepted: 18 February 2025

Published: 24 February 2025

Citation: Borkow, G.; Melamed, E. The Journey of Copper-Impregnated Dressings in Wound Healing: From a Medical Hypothesis to Clinical Practice. *Biomedicines* **2025**, *13*, 562. <https://doi.org/10.3390/biomedicines13030562>

Copyright: © 2025 by the authors. Licensee MDPI, Basel, Switzerland. This article is an open access article distributed under the terms and conditions of the Creative Commons Attribution (CC BY) license (<https://creativecommons.org/licenses/by/4.0/>).

Keywords: copper oxide; wound dressings; wound healing; angiogenesis; extracellular matrix; chronic wounds

1. Chronic Wounds

Chronic wounds, defined as wounds that fail to proceed through an orderly and timely reparative process, affect a significant portion of the world population. As the life expectancy of the worldwide population is increasing, the prevalence of chronic wounds, such as venous ulcers, pressure sores, and diabetic ulcers, is also dramatically increasing, particularly in developed countries. The global prevalence of venous ulcers is estimated to be around 1% of the general population, increasing to approximately 3% in individuals over 65 years of age [1]. A 2019 study estimated the global diabetes prevalence at 9.3%

(463 million people), which is projected to rise to 10.2% (578 million) by 2030 and 10.9% (700 million) by 2045 [2]. A meta-analysis by Li et al. [3] reported a pooled global prevalence rate of 12.8% for pressure ulcers, indicating that approximately one in eight individuals in healthcare settings may be affected. A meta-analysis of studies analyzing chronic wounds in the general population estimated a pooled prevalence of 2.21 per 1000 people in the population for chronic wounds of mixed etiologies, and 1.51 per 1000 for chronic leg ulcers [4]. In the United States, chronic wounds impact the quality of life of nearly 2.5% of the total population, with a higher prevalence observed among the elderly [5]. In Germany, in 2012, approximately 1.04% of insured patients had a wound diagnosis, with 0.70% having leg ulcers and 0.27% diabetic ulcers [6]. Extrapolated to the national level, this equates to about 786,407 individuals with chronic wounds. Taken together, it is clear that chronic wounds are an alarming increasing global problem, causing enormous cost burdens to both patients and healthcare providers [7].

The healing of wounds follows a precisely regulated and systematic process consisting of three overlapping phases after hemostasis: inflammation (lasting 4 to 6 days), proliferation (spanning 4 to 24 days), and remodeling (which can extend from 21 days up to 2 years). These biological events involve various cellular and molecular mechanisms, including cell migration, differentiation, and proliferation. When a wound occurs, changes in the microenvironment, such as decreased oxygen levels, trigger the release of specific factors from fibroblasts, epidermal cells, macrophages, and vascular endothelial cells, promoting the formation of new blood vessels (angiogenesis). Among these factors, vascular endothelial growth factor (VEGF) plays a dominant role in driving angiogenesis, while Transforming Growth Factor-beta (TGF- β), particularly TGF- β 1, is crucial for regulating the production of elastin and collagen. Fibroblasts synthesize and secrete these structural proteins, which then undergo cross-linking to form the extracellular matrix (ECM) of the dermis. This process is essential for restoring the structural integrity and function of the damaged tissue.

Chronic wounds, also referred to as “hard-to-heal wounds”, become stalled in one or more stages of the healing process, with some taking years to close completely or failing to heal altogether. One of the major processes that do not occur in chronic wounds is the production of new blood capillaries. Chronic wounds are characterized by extensive loss of the integument, necrosis, or signs of circulation impairment. These wounds are associated with high morbidity and mortality due to tissue inflammation, ischemia, and infection [8–10].

Wound infections delay wound healing [11] by producing inflammatory mediators, metabolic wastes, and toxins; causing tissue hypoxia and hemorrhagic and fragile granulation tissue; reducing fibroblast number and total collagen production; interfering with re-epithelialization [12,13]; and reducing the available nutrients and oxygen needed by the host cells and causing neutrophils to be in an activated state producing cytolytic enzymes and free oxygen radicals [14]. Bacteria are usually protected by biofilm in chronic wounds [11]. Thus, reducing the microbial contamination of wounds increases the capacity of the wound to heal.

2. The Role of Copper in Wound Healing

Copper is a vital trace element that plays a role in numerous physiological functions across all body tissues, including the skin and integumentary system [15–18]. Several crucial wound healing mechanisms rely on copper for proper function [19,20]. These include the regulation of key growth factors such as VEGF and angiogenin, which drive angiogenesis during the proliferation phase [21–25]; the production of collagen (types I, II, and V) and elastin fibers by dermal fibroblasts, which are essential for tissue formation in the proliferation and remodeling phases [26–28]; and the activity of lysyl oxidase (LOX),

which facilitates cross-linking between collagen and elastin, ensuring the stability of the ECM [29–31]. Additionally, copper influences integrin modulation via differentiated keratinocytes in the remodeling phase and is involved in the function of matrix metalloproteinases (MMPs) and serine proteases, such as human neutrophil elastase (HNE), which contribute to the wound healing process [32–36]. As a cofactor of superoxide dismutase [23], an antioxidant enzyme present in the skin, copper helps mitigate oxidative stress by preventing membrane damage and lipid peroxidation. Copper is also a cofactor of tyrosinase [37], the enzyme responsible for melanin production, which plays a role in skin and hair pigmentation, particularly during the maturation phase of wound healing. The essentiality of copper in the natural physiological wound healing processes is now very well established [20].

Other natural trace elements play an important role in wound healing. For example, cobalt is an essential component of vitamin B12 (cobalamin), which is crucial for red blood cell formation, DNA synthesis, and cellular metabolism—important factors in tissue repair. Additionally, cobalt has been shown to stimulate angiogenesis. Recent research has explored the use of cobalt-releasing bioactive glass compositions as scaffold materials to locally deliver pro-angiogenic cobalt ions at a controlled rate, aiming to promote wound healing [38,39].

3. Copper as a Wide Spectrum Antimicrobial Tool

Copper is also an essential mineral required for the normal functioning of microorganisms [40]. However, microorganisms must carefully regulate intracellular copper levels. Under anaerobic conditions, copper exists predominantly in its highly reactive cuprous form (Cu^+), which readily interacts with microbial proteins, disrupting their structure by forming thiolate bonds with iron–sulfur clusters [41]. When microorganisms are exposed to excessive concentrations of copper, they are unable to manage the surplus, leading to their death [42,43].

The potent biocidal activity of copper is attributed to several mechanisms. It is likely that the first site damaged by copper is the microorganism's envelope [42]. Significant copper-induced disruption of membrane integrity ultimately results in a loss of cell viability. However, even minor changes in the physical properties of biological membranes can profoundly affect essential membrane-dependent functions, such as transport protein activity and ion permeability [44]. Once inside the cell, copper can displace essential metals from their native binding sites within proteins or interact directly with the proteins. The redox cycling between Cu^+ and Cu^{2+} generates hydroxyl radicals, which preferentially target amino acids such as histidine and proline. This process can cause significant protein alterations, including structural modifications and, in some cases, protein cleavage [45,46]. These disruptions often result in conformational changes to the protein structure or active site, ultimately inhibiting or neutralizing the proteins' biological functions. Copper ions may also interact with nucleic acids, especially in viruses, causing damage to the genetic material [42]. Copper's multisite, non-specific mechanism of action, which simultaneously targets and damages multiple critical components of microorganisms, makes the development of resistance to copper exceedingly difficult [42]. In stark contrast to the widespread resistance microorganisms have developed to antibiotics within just 50 years of their use, resistance to copper remains exceptionally rare, despite copper's presence on Earth for millions of years.

4. Do Chronic Wounds Not Heal Due to Insufficient Local Copper Levels?

In 2008, we hypothesized that chronic wounds may not heal due to the lack of systemic copper that reaches the wound [19]. We based our hypothesis on the key role that copper

plays in the main wound healing processes, i.e., induction of angiogenesis, secretion of extracellular matrix skin proteins, and epithelialization. We hypothesized that in individuals with diabetic ulcers, pressure sores, peripheral vascular wounds, or other injuries with potentially compromised circulation to the wound site, a contributing factor to impaired healing may be insufficient local copper levels. We further theorized that constant in situ exposure of copper ions to the wound site would enhance wound repair by inducing angiogenesis and upregulating specific elements that are critical for the healing process and are stagnated in chronic wounds [19]. We envisioned that incorporating copper into wound dressings could not only minimize the risk of wound and dressing contamination, similar to silver, but also actively promote faster wound healing. This effect would be achieved through the controlled release of copper from the dressings directly into the wound site, stimulating angiogenesis and facilitating skin regeneration.

To validate our hypothesis, we developed wound dressings impregnated with cuprous oxide microparticles [47]. On the one hand, we endowed the dressings with potent biocidal properties [47,48], and on the other hand, these dressings served as a sustained-release reservoir for copper ions and are capable of continuously delivering copper ions to the wound bed, without causing any adverse reactions [47]. We then evaluated the dressings in aseptic wound models using genetically engineered diabetic mice. Wounds were treated with either control dressings (lacking copper), commercially available silver dressings, or copper oxide-impregnated dressings. The mice treated with copper oxide-impregnated dressings exhibited a statistically significant acceleration in non-infected wound closure compared to those treated with silver or control dressings [49]. Histopathological analysis of skin specimens from the mice treated with copper dressings revealed normal histology with no evidence of atypia. Furthermore, the copper-treated wounds displayed earlier epidermal regeneration, enhanced granulation tissue formation, increased angiogenesis, and the emergence of new hair follicles and sebaceous glands.

Immunohistochemistry staining provided clear evidence of significantly enhanced angiogenesis in the copper-treated mice. Further investigation of mRNA expression levels in wound sites, analyzing 84 genes alongside immunohistochemistry staining, demonstrated the upregulation of multiple angiogenic factors, including placental growth factor (PGLF), vascular endothelial growth factor (VEGF), and hypoxia-inducible factor-1 alpha (HIF-1 α). A proposed molecular mechanism suggests that the redox cycling between Cu⁺ and Cu²⁺ creates a hypoxic environment, triggering the increased expression of HIF-1 α in the dermis. This upregulation of HIF-1 α then initiates a cascade of biological processes, promoting endothelial cell proliferation and migration, angiogenesis, immune cell infiltration, fibroblast activation, heightened metabolic activity, enhanced extracellular matrix protein secretion, and accelerated epithelialization [49].

Hypoxia-inducible factor-1 (HIF-1) deficiency and subsequent failure to respond to hypoxic stimuli leads to chronic hypoxia, which has been shown to contribute to the formation of non-healing ulcers [50]. HIF-1 α , a subunit of the transcription factor hypoxia-inducible factor-1 (HIF-1), is now accepted as an important target for the enhancement of wound healing [50–52]. Copper is required for HIF-1 activation through the regulation of HIF-1 α binding to the hypoxia-responsive element (HRE) and the formation of the HIF-1 transcriptional complex [53]. It has also been demonstrated that copper regulates HIF-1 transcription activity by affecting the selectivity of HIF-1 α binding to the promoters of affected genes [54]. HIF-1 α is not responsive in diabetics [55,56], as hyperglycemia impairs the HIF-1 α transactivation, resulting in decreased hypoxia-induced VEGF expression [57]. HIF-1 abnormal expression also probably occurs in other chronic wounds, as it occurs in other diseases (e.g., rheumatoid arthritis [58]).

Das et al. [59] confirmed our findings by investigating the role of the copper-dependent transcription factor and copper chaperone Antioxidant-1 (Atox1), which maintain intracellular copper homeostasis and play a role in wound healing. They demonstrated that topical treatment with copper of cutaneous wounds inflicted in wild-type mice accelerated wound closure. Furthermore, they found that treatment of the wounds with a copper chelator delayed the healing process. They also found that wounding markedly increased the expression of Atox1, but not of other copper chaperons. Taken together, their studies demonstrated how exogenous and endogenous copper accelerates wound healing via Atox1. Coger et al. found an immediate increase in the concentration of copper in a full-thickness open-wound rat model following wounding of ~40% within 2 days [60]. Lansdown et al. found a marginal increase in the copper concentration in the 2 days following wounding in a similar wound rat study [61]. These studies indicate that part of the normal physiological response to wounding is to deliver more copper to the wound. Yi et al. found that SLC31A1, a copper transporter, was significantly downregulated in refractory diabetic foot ulcers (DFUs) as compared to healthy controls and acute traumatic wounds [62]. This study supports our hypothesis that less copper is delivered to chronic wounds, which impairs the key wound healing processes. Yadav et al. found that the mean serum copper levels in diabetes patients with foot ulcers were significantly decreased as compared to diabetic patients without ulcers [63]. While not direct proof, this finding supports the hypothesis that reduced copper serum concentration in diabetic patients may impede wound healing, resulting in chronic foot ulcers.

5. Further Laboratory and Animal Studies Supporting the Key Role That Copper Plays in Wound Healing

In recent years, an increasing number of studies have explored copper-containing biomaterials, particularly those incorporating copper nanoparticles (less than 100 nm in diameter) into polymeric scaffolds and hydrogels, for wound healing applications [64–70]. These studies consistently demonstrate enhanced healing of non-infected wounds [71–76], including those in diabetic [77–83] and burn-related [84–90] animal models when compared to control materials. Additionally, copper-containing biomaterials, mostly wound dressings, have shown significant potential in promoting the healing of infected wounds [68,87,91–98], including those infected with MRSA [99] and *Escherichia coli* biofilm [100]. Notably, they have also been effective in diabetic wound models infected with *Staphylococcus aureus* [83,101,102] and MRSA [103]. Recently, due to their large surface area, fast degradation, and transformation into hydroxyapatite (HA), as well as their ease of handling and adaptability in shape, bioactive glass microfibers doped with copper or cobalt have gained increasing attention to serve as a substrate for their potential in promoting wound healing [38,39,69,70]. One of the notorious effects noticed in some of these studies was the significant increase in VEGF and the number of blood vessels in the copper-treated wounds as compared to the controls [72,73,75,77,78,84,97,103]. Many of these studies also demonstrated other increased wound healing processes throughout the wound healing phases, such as increased extracellular matrix deposition, increased nerve regeneration, hair follicle regeneration, and fibroblast and endothelial cell migration and epithelialization and reduced inflammation in the groups of animals treated with the copper-containing biomaterials (e.g., [72,80,82,94,97,103]). Copper-eluting fibers have been shown to enhance the approximation and healing of incisional wounds, including increased angiogenesis around the incision site [104].

It is now well accepted by the scientific community that copper plays a key role in the wound healing processes [20] and systematic reviews of the literature clearly support the notion that in situ exposure of wounds by copper-containing biomaterials enhances the

wound healing processes (e.g., [67,105,106]). Despite the vast number of studies showing the potential of enhancing wound healing through copper-containing dressings, to the best of our knowledge, the only copper-containing wound dressings currently in clinical use for human wound management are those produced by MedCu Technologies Ltd. (www.medcu.com, Accessed on 1 January 2025). These dressings (MedCu Antimicrobial Wound Dressings with Copper-Oxide; hereafter referred to as copper dressings) containing cuprous oxide microparticles have successfully passed comprehensive biocompatibility and safety evaluations, and have been approved by multiple regulatory bodies, including the FDA and CE, for the treatment of acute and chronic wounds. Commercially launched in 2019, these dressings are now in clinical use in over 25 countries.

6. Clinical Applications of Copper Dressings

Numerous studies have demonstrated the ability of copper dressings to enhance healing in hard-to-heal wounds, including both infected and non-infected wounds, across all stages of the healing process [107–122]. These studies covered a range of chronic wounds, such as diabetic ulcers, venous ulcers, pressure sores, venous harvesting site wounds, non-healing post-amputation wounds, necrotic wounds, and acute conditions like burns and clean orthopedic surgery wounds. Copper dressings were effective even in patients with challenging conditions such as diabetes mellitus, renal failure, inflammatory diseases, and sickle cell disease, as well as in locally compromised tissue due to ischemia, post-irradiation effects, extensive necrosis, and/or contamination. Across these studies, copper dressing application consistently led to significant improvements in wound healing, including in stagnant, non-infected, and non-healing wounds [109,110,112–115,119–121]. An example of such a study was the treatment of diabetic non-infected wounds (wound area range between 1.35 and 23.6 cm²) where, during the screening period, the wounds were non-responsive to the standard of care wound dressing management. However, when the copper dressings were applied twice weekly for a month, there was a 53.2% mean wound area reduction ($p = 0.003$) (Figure 1) and a 43.37% increase in mean granulation tissue formation ($p < 0.001$) [110].

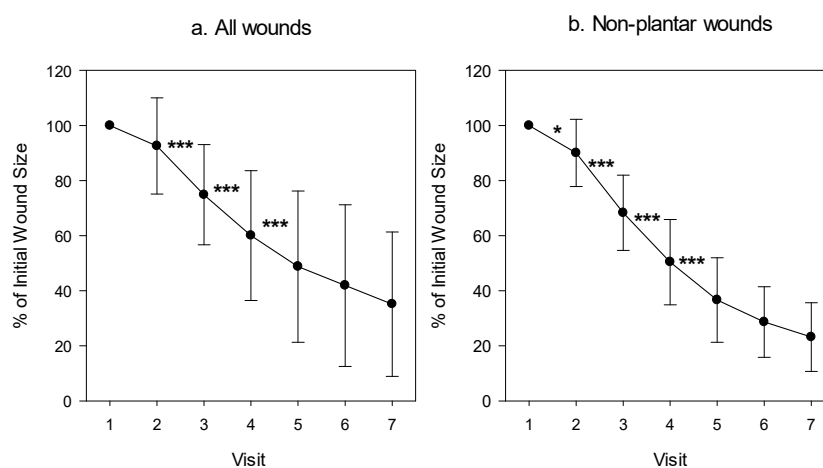


Figure 1. Percent of wound area during the trial as compared to the wound size at the commencement of the study. The mean \pm standard deviation of the wound area of (a) all patients and (b) of those suffering from a non-plantar foot wound. A paired t-test was conducted between each visit and the subsequent one. * $p < 0.05$; *** $p < 0.001$ [110].

The study by Gorel et al. [113] conducted in a rehabilitation center, in 2–30 cm² non-infected wounds treated for 17–41 days with silver wound dressings that failed to reduce the wound size by >50%, is another relevant example. Ten patients were diabetics, ten

suffered from hypertension, and six suffered from peripheral vascular disease (PVD). Once they switched the silver dressings to copper dressings, comparing during a period of 25 days, the mean wound area reduction was ~2.4 times higher during the copper treatment phase than during the silver dressing treatment phase (87% versus 37% ($p < 0.001$)). Some of the patients' wounds responded quite immediately to the exposure to the Copper dressings and their size was reduced quickly (Figure 2).

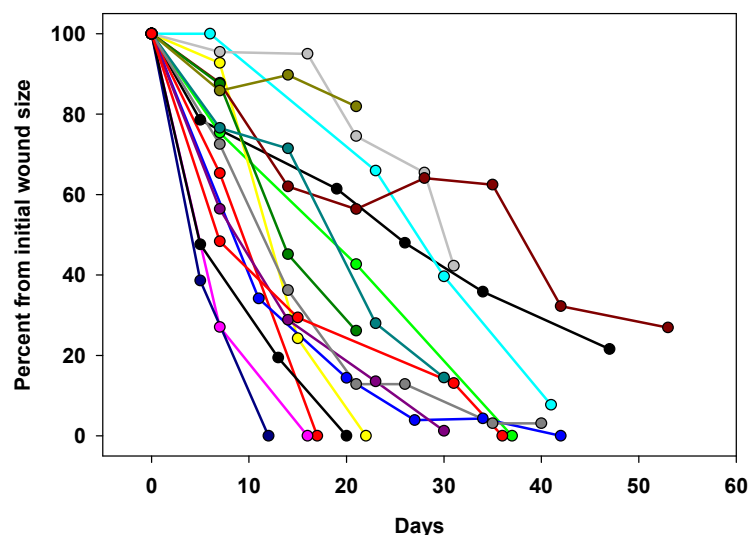


Figure 2. Wound healing progression during the use of the copper dressings. Each line represents the size of the wound per each patient after normalization to the start of the wound size at the commencement of the copper dressing use [113].

These studies indicate that the wound healing benefits of copper dressings extend beyond their antimicrobial properties.

Clinical cases have demonstrated the effectiveness of copper dressings in several aspects of wound care, including infection clearance [107,109,111], induction of granulation and epithelialization in necrotic wounds [107,109,111], reduction in post-operative swelling and inflammation, and minimization of scar formation [107]. Notably, these dressings have shown positive outcomes across all stages of wound healing [107,108], supporting a continuum of care from skin rupture to complete closure [108]. The use of copper-containing dressings should be avoided in cases of known allergy to copper or in oncological active wounds.

A recent randomized clinical trial demonstrated that the copper dressings were non-inferior to negative pressure wound therapy (NPWT) in achieving wound size reduction and promoting granulation tissue formation in diabetic ulcers [122]. More specifically, 46 diabetic patients, with non-infected wounds ranging between 1.56 and 44.56 cm², who necessitated NPWT for closure after recovering from wound infections that required extensive debridement surgery and/or partial foot amputation, were randomly allocated to either receiving NPWT or copper dressings. The wound measurement and condition assessed for 13 weeks using a 3D Wound Imaging System App demonstrated no statistically significant differences between both arms in wound size reduction and granulation tissue formation. Moreover, the use of copper dressings was significantly more convenient for both patients and healthcare providers, reducing wound management costs to approximately 15% of those associated with NPWT.

7. Case Samples

7.1. Clearance of Infection, Induction of Granulation, and Epithelialization [107]

A 57-year-old male with a history of non-insulin-dependent diabetes mellitus (NIDDM) presented with ulcers on both feet, predominantly affecting the right side. The primary cause was attributed to an acute leukocytoclastic vasculitis reaction, with minimal involvement of major arteries. To address this, an angiographic procedure was performed, including percutaneous reopening of the superficial femoral artery. Treatment consisted of high-dose corticosteroids, immunosuppressive therapy (Azathioprine and Imuran), and broad-spectrum antibiotics. Despite these interventions, the condition of the right foot deteriorated, leading to necrosis primarily affecting the medial toes. The infection advanced, compromising the tendons and plantar fascia. Additionally, deep ulcers developed on the medial side of the heel and the lateral part of the foot (Figure 3a,b). The patient underwent surgical debridement, including the amputation of the first and second rays. Intraoperative cultures identified *Pseudomonas aeruginosa* as resistant to quinolones, prompting treatment with Imipenem. However, five days later, the patient required a trans-metatarsal amputation. The wound was only partially closed to avoid a loose flap, but within days, necrosis developed at the flap edges (Figure 3c). Bedside debridement was performed, and cultures from this second surgery revealed that the *Pseudomonas* had developed resistance to carbapenems, leading to the discontinuation of antibiotic therapy. At this point, approximately 30% of the medial heel wound and 80–90% of the lateral anterior wound were necrotic (Figure 3c,d).

A trans-tibial amputation was considered the next step. The patient's white blood cell count had decreased to 18,000, an improvement from previous levels, and C-reactive protein (CRP) was measured at 3.0 (normal <0.5). However, given the patient's overall stable condition, it was decided to proceed with local wound care using copper dressings. Copper dressings were applied deep in the plantar fascia portion of the amputation wound, along the wound edges, and over the ulcers (Figure 3d,e). These were changed twice weekly, with Prontosan® irrigation recommended during dressing changes. No additional antibiotic therapy was administered.

Gradual improvement in the foot's condition was observed. The superficial semi-necrotic ulcer on the heel and lateral foot progressively absorbed necrotic tissue, forming granulation tissue and epithelializing (Figure 3f–i). The primary amputation wound, which had a significant cavity of 6–7 cm, slowly filled with granulation tissue (Figure 3g). Autolysis (self-debridement) of necrotic tissue was also noted (Figure 3i), and new epithelial layers progressively covered the healing wounds (Figure 3g,h). A microbial culture taken three months after stopping antibiotics showed no presence of *Pseudomonas*, though non-pathogenic colonizing bacteria were detected.

After five months of copper dressing treatment, both the medial and lateral wounds had fully closed (Figure 3j,k). The primary amputation site was partially closed, with the remaining wound area covered in healthy pink to red granulation tissue (Figure 3l).

7.2. Promotion of Epithelialization [107]

The remarkable ability of copper dressings to enhance epithelialization is demonstrated in the case of a 71-year-old man with NIDDM and diabetic neuropathy. He developed osteomyelitis of the calcaneus, requiring extensive debridement of both the heel and the infected bone. However, the wound failed to heal, and due to the missing bone, the calcaneus collapsed through a weakened area, resulting in a rocker-bottom deformity. To address this, the patient underwent another surgical procedure involving soft tissue debridement, realignment of the foot, and fixation with Steinman pins (Figure 4a,b, one week post-surgery).

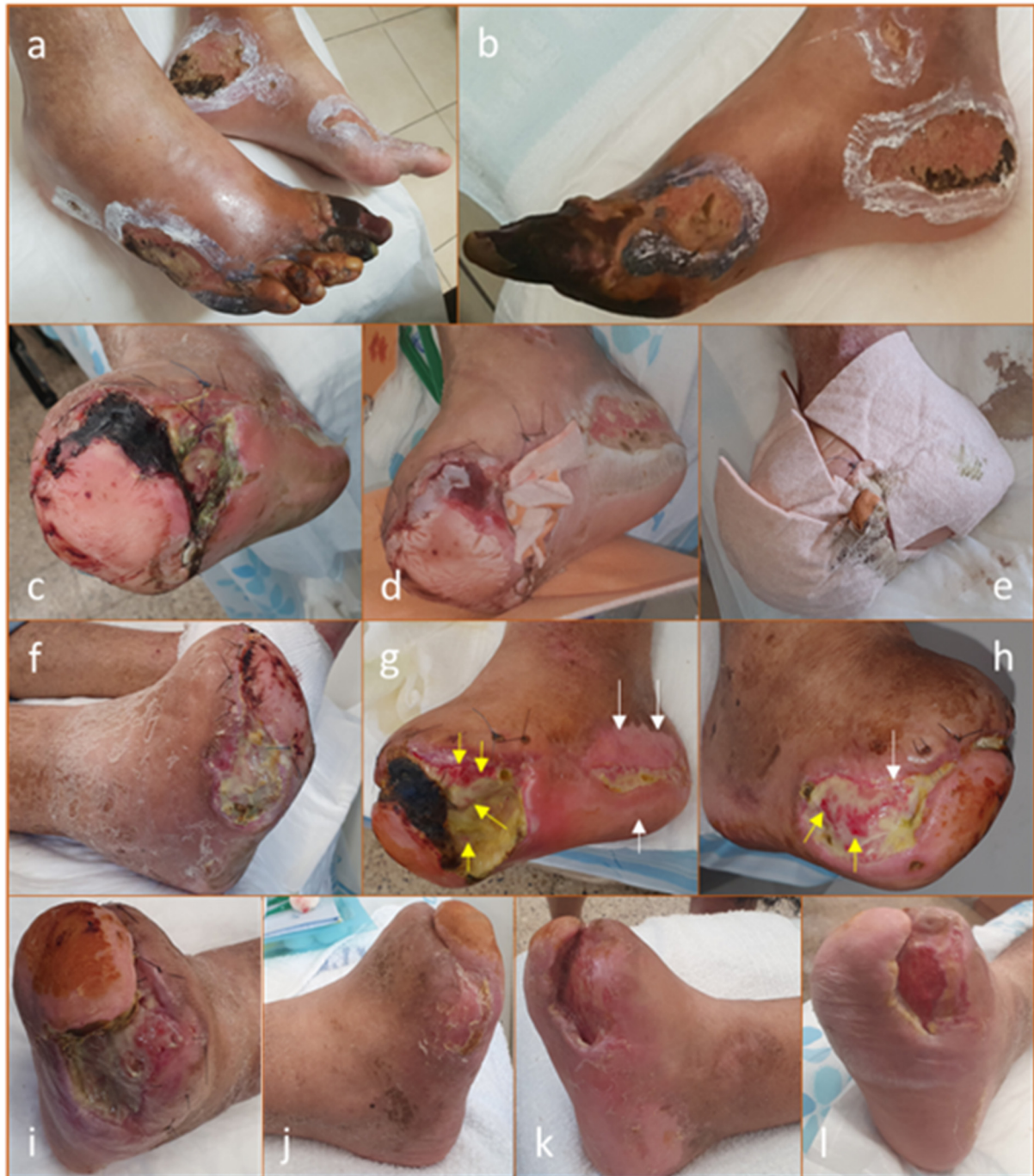

Figure 3. Resolution of Infection, Granulation Induction, and Epithelialization of Necrotic Wounds. (a). Ulcers colonized with *Pseudomonas aeruginosa* were present on both feet, predominantly on the right foot. (b). The ulcers were located on the medial aspect of the heel and the lateral side of the foot. (c). Two weeks post-transmetatarsal amputation, necrotic tissue was observed at the edges of the partially closed flap. (d). Copper dressings were first applied (Day 0), placed deep within the plantar-fascial region of the amputation wound. (e). Additionally, the dressings were used to cover both the medial and lateral ulcers. (f). After one-week, necrotic tissue had reduced, and granulation tissue formation had begun in all wounds. (g,h). After two months of copper dressing treatment, clear epithelialization (white arrows) was observed in the medial and lateral ulcers, while granulation tissue (yellow arrows) was evident in these ulcers and the central amputation wound, visible beneath a thin layer of residual necrotic tissue. Cultures from the necrotic tissue were negative for *Pseudomonas*, the initial resistant pathogen. (i). The granulation tissue appeared to facilitate necrotic tissue autolysis (self-debridement). (j,k). By five months of copper dressing treatment, the medial and lateral ulcers had completely closed. (l). The primary wound was partially closed, with the remaining area covered in healthy pink to red granulation tissue.

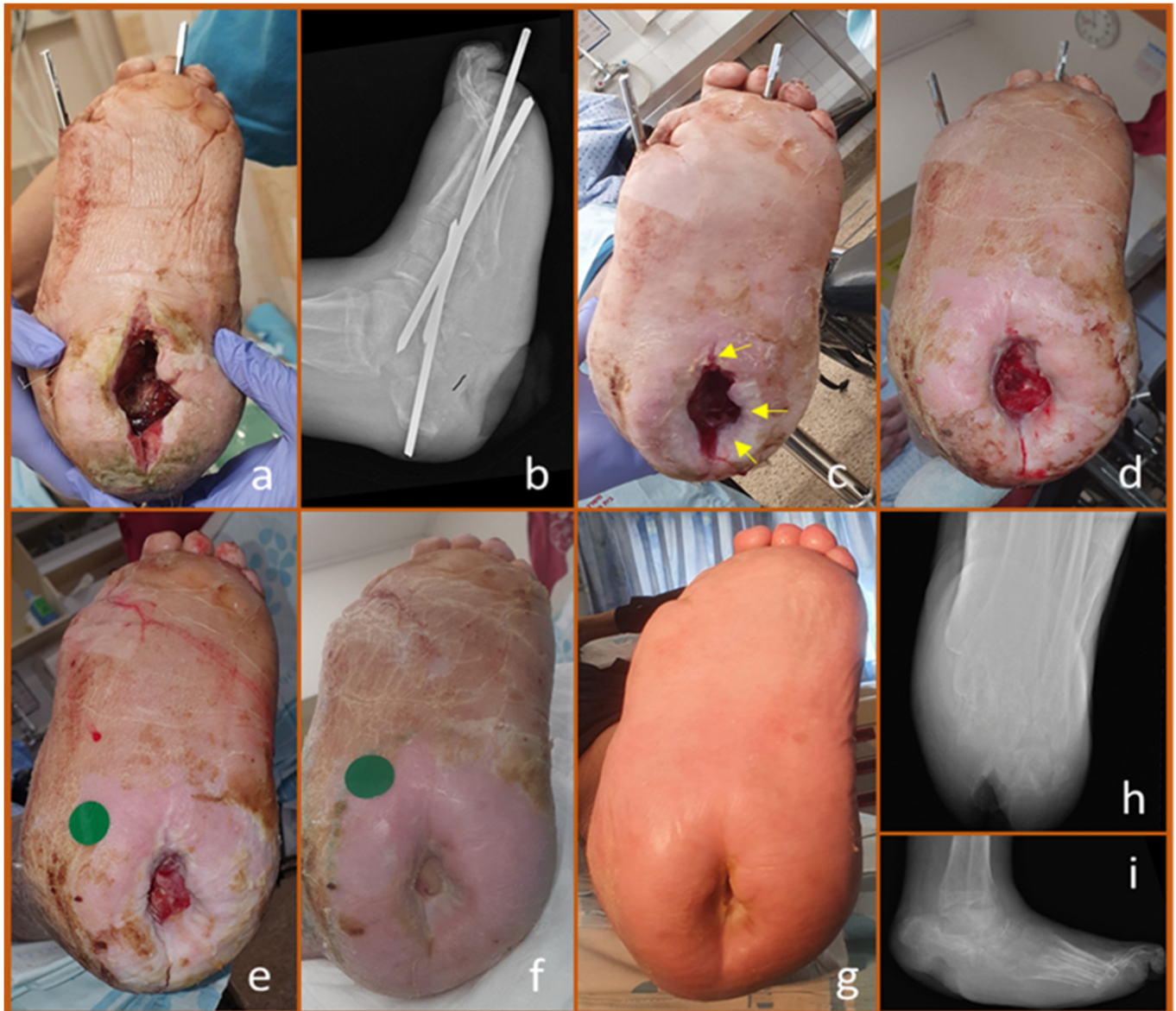


Figure 4. Epithelialization of a Plantar Deep Wound Associated with Rocker Deformity. The patient underwent resection of an infected calcaneal bone, followed by correction and stabilization of the resulting rocker deformity using Steinman pins. Copper dressings were applied during surgery. (a). One-week post-surgery, the deep calcaneal wound was visible without signs of infection. (b). X-ray showing the inserted Steinman pins, with the missing plantar calcaneal bone and the deep soft tissue void beneath it. (c). Three weeks after surgery, copper dressings treatment promoted the migration of epidermal tissue from the wound edges into its depth. (d,e). Continued epithelialization was observed over the granulation tissue at 7 weeks (d) and 8 weeks (e) of copper dressings treatment. (f). At 3.5 months, significant wound closure was evident. (g). By 4.5 months, the wound had achieved 95% closure. (h,i). Lateral and axial calcaneal X-rays at 4.5 months post-surgery revealed a large soft tissue void, now covered with nearly normal-appearing skin. Throughout the entire period, the foot was treated exclusively with copper dressings.

During and after surgery, the wound was treated with copper dressings, which were changed weekly. Rapid granulation tissue formation was observed, filling both the depth and walls of the large wound cavity. Simultaneously, healthy skin from the wound edges began migrating inward. A photograph taken three weeks post-surgery (Figure 4c) shows early epithelialization at the superficial cavity wall (indicated by arrows). This process continued over time, as seen in images taken at 7 and 8 weeks (Figure 4d,e), as well as at 3.5

and 4.5 months post-surgery (Figure 4f,g). Corresponding X-rays at 4.5 months are shown in Figure 4h,i.

7.3. Reduction in Post-Operative Swelling Inflammation [107]

A 62-year-old man presented with degenerative changes in the first metatarsophalangeal joint (Hallux Rigidus) and metatarsalgia. His forefoot deformities included hallux valgus interphalangeus, subluxation of the lesser MTP joints, a hammer toe deformity of the second toe, and a bunionette deformity (Figure 5a). The surgical intervention involved a cheilectomy of the first metatarsal head, an Akin–Moberg osteotomy at the base of the proximal phalanx of the big toe, Weil osteotomies of the second and third metatarsals, a Chevron osteotomy of the fifth metatarsal, and PIPJ arthrodesis to correct the second hammer toe (Figure 5b).

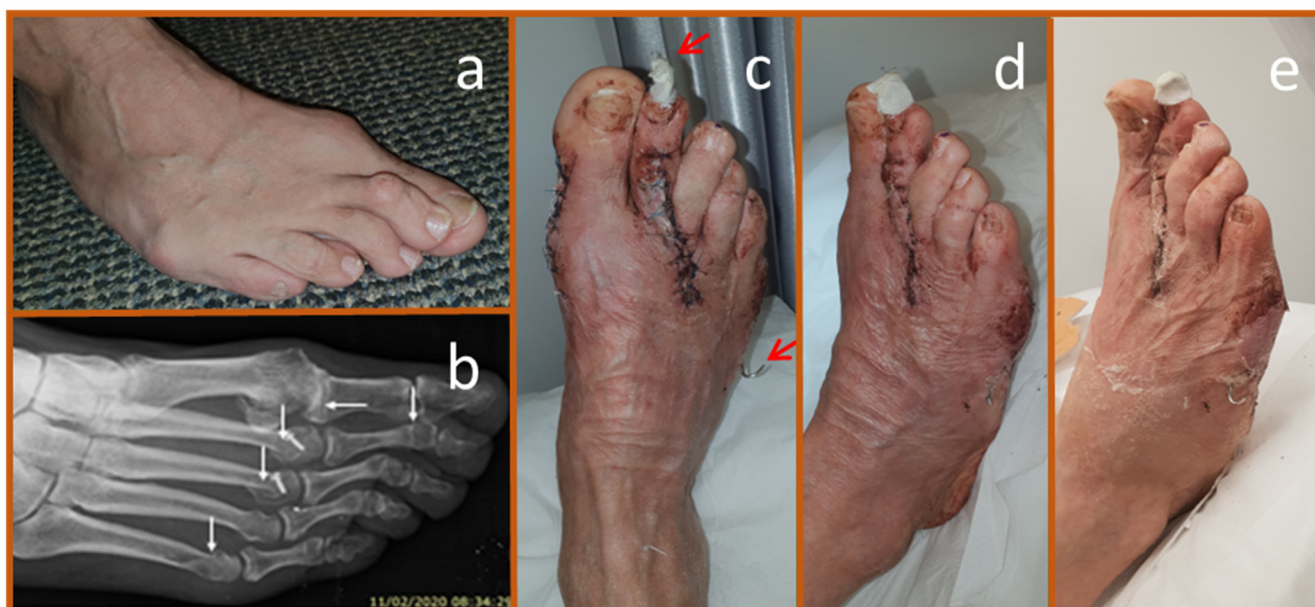

Figure 5. Reduction of Swelling Following Forefoot Surgeries and Osteotomies. (a). Preoperative forefoot deformities, including hallux valgus, hammer toe of the second digit, subluxation of the 2nd and 3rd metatarsophalangeal joints, and a Bunionette deformity. (b). X-ray taken two months post-surgery showing osteotomy of the proximal phalanx base of the big toe, Weil osteotomies of the 2nd and 3rd metatarsals, Chevron osteotomy of the 5th metatarsal, and PIPJ arthrodesis of the 2nd hammer toe (arrows). (c). Clinical image at the first dressing change, three weeks after surgery (copper dressings were applied intraoperatively), showing well-healing surgical wounds without signs of inflammation. The absence of swelling and the presence of skin wrinkles are notable. The tips of the K-wires stabilizing the 2nd toe and 5th metatarsal are visible (marked with red arrows); the second toe K-wire is wrapped in plaster to prevent accidental pullout. (d). Oblique view of the same foot at the same visit, after suture removal, clearly demonstrating reduced swelling. (e). Clinical images at five weeks post-surgery showing maintained skin wrinkles and continued absence of swelling.

Fixation was achieved using Kirschner wires (KWs) for the second toe and fifth metatarsal, screws for the second and third metatarsals, and an absorbable suture for the proximal phalanx osteotomy of the big toe. Following surgery, copper dressings were applied immediately, with the first dressing change performed after three weeks. At that time, the surgical wounds showed no signs of infection or inflammation (Figure 5c). Remarkably, despite undergoing four metatarsal osteotomies and a toe arthrodesis, there was minimal swelling, allowing the natural skin wrinkles to remain visible (Figure 5c–e).

This outcome contrasts sharply with the significant swelling typically observed for several months following foot osteotomies.

7.4. Reduction in Scar Formation [107]

A 20-year-old healthy woman underwent bunion surgery, which involved a Chevron-type osteotomy of the first metatarsal with fixation using Kirschner wires (KWs) (Figure 6a). Two weeks post-surgery, both the surgical incision and the KWs were visible in clinical photos and X-rays (Figure 6a,b). The KWs were removed at four weeks, by which time the surgical incision had healed well (Figure 6c,d). At seven weeks post-surgery, the osteotomy had fully healed, with a satisfactory clinical outcome. (e,f). The surgical scar appeared very delicate. (g). Comparison between the original incision and its appearance at seven weeks demonstrated that approximately 80% of the scar was no longer visible, even under high-resolution magnification. This suggests either direct epithelialization or significant scar remodeling.

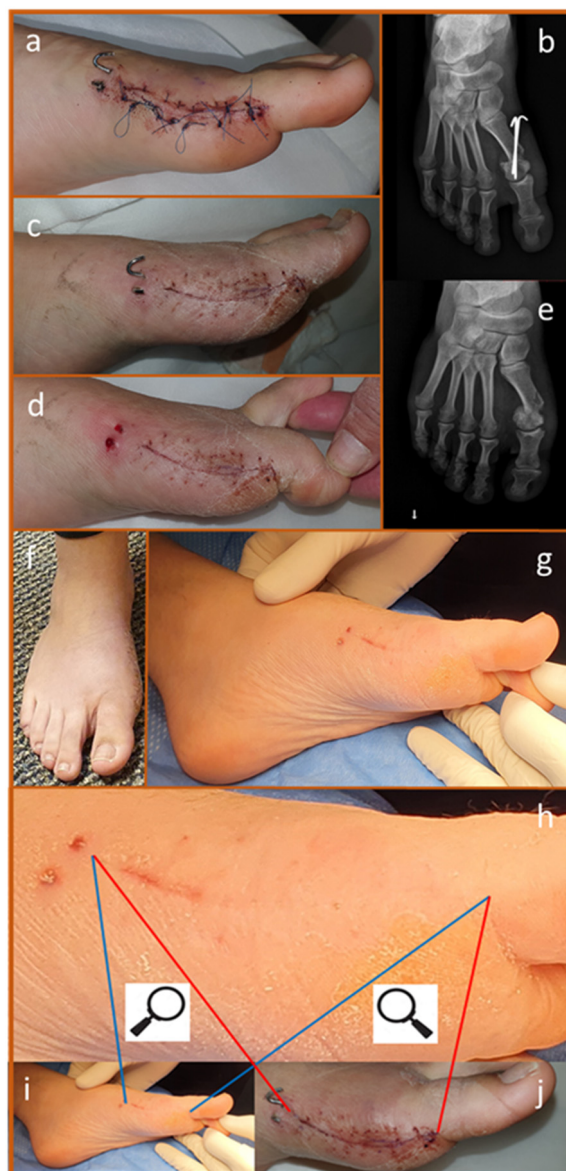

Figure 6. (a,b). Clinical and radiographic images taken two weeks post-surgery, showing the surgical incision and the K-wires in place. (c,d). By four weeks, the K-wires were removed, and the surgical incision showed good healing. (e,f). At seven weeks post-surgery, the osteotomy had fully healed, with a satisfactory clinical outcome. (g). The surgical scar appeared very delicate. (h–j). Comparison between the original incision and its appearance at seven weeks demonstrated that approximately 80% of the scar was no longer visible, even under high-resolution magnification. This suggests either direct epithelialization or significant scar remodeling.

At seven weeks post-surgery, the osteotomy had fully healed, and the clinical outcome was satisfactory (Figure 6e,f). The surgical scar appeared very faint (Figure 6g). A comparison of the initial incision with its appearance at seven weeks revealed that approximately 80% of the scar was no longer visible, even under high-resolution and magnified photography (Figure 6h–j). This suggests that either direct epithelialization occurred or scar remodeling took place. The exceptional cosmetic results at seven weeks go beyond what is typically expected from a successful case, leading us to attribute this outcome to the positive effects of the copper dressings on wound healing.

8. Conclusions

Copper exhibits a broad spectrum of antimicrobial activity similar to silver. However, unlike silver, copper is an essential element for bodily functions and nutrition, and it is not cytotoxic. MedCu copper dressings incorporate microparticles of cuprous oxide, which act as a reservoir for copper ions. These ions are released gradually and consistently into the wound at parts-per-million (ppm) levels, maintaining an optimal concentration of copper ions. This controlled release stimulates the production of cytokines and growth factors, promoting angiogenesis and granulation tissue formation.

Additionally, copper ions act as cofactors for enzymes involved in wound healing, such as elastases and metalloproteinases. These enzymes facilitate the autolysis of necrotic tissue, contributing to copper dressings' potent debridement effect. The presence of copper also enhances epithelial migration, accelerating wound closure and, in some cases, eliminating the need for skin graft surgeries.

All these actions occur simultaneously, with copper also providing antibacterial protection to the wound. As a result, copper supports all stages of wound healing and addresses the essential elements of this complex physiological process. This clinical observation, which is in line with basic science, led us to formulate the concept of a "Continuum of Care through all phases of wound healing". This concept is important because it means that whenever the caregiver debates which treatment the wound needs now, with copper dressings, they cannot be wrong.

The growing number of independently conducted animal and laboratory studies, as described in Section 5, all demonstrating the positive effects of copper-containing biomaterials—primarily dressings—on wounds, reinforces our findings and supports the conclusion that copper-containing dressings will play a vital role in the expanding the "arsenal" of wound healing interventions available to practitioners.

9. Future Directions

In this article, we explored the use of copper dressings in managing chronic wounds. However, based on our clinical experience, we believe that copper-containing dressings can also be highly beneficial in treating acute wounds, such as surgical wounds, skin tears, abrasions, lacerations, and burns. In such cases, we have observed a significant reduction in wound complications, such as dehiscence and infections, as well as a noticeable decrease in scarring.

Given copper's essential role in all physiological processes of wound healing, we have seen its beneficial effects across all stages of the healing process. The ability to use a single dressing effectively from the initial wound occurrence to full closure—particularly by general practitioners rather than specialized wound care experts—could greatly enhance the efficiency of wound management. This is especially important in developing countries, where wound specialists may be scarce and access to effective treatments is limited.

To further validate these observations, large-scale clinical trials involving a diverse range of wound types and indications should be conducted to clearly establish copper-containing dressings as a potential “game changer” in wound management.

Author Contributions: G.B. and E.M. contributed to the design and writing of the article. All authors have read and agreed to the published version of the manuscript.

Funding: This research received no external funding.

Conflicts of Interest: G.B. is the chief scientist and cofounder of MedCu Technologies. E.M. serves as a consultant for MedCu Technologies.

Abbreviations

The following abbreviations are used in this manuscript:

VEGF	Vascular endothelial cell growth factor
TGF- β	Transforming Growth Factor- β
ECM	Extracellular matrix
LOX	Lysyl oxidase
MMP	Matrix metalloproteinases
HIF-1	Hypoxia-inducible factor-1
MRSA	Methicillin-resistant <i>Staphylococcus aureus</i>
NPWT	Negative pressure wound therapy
NIDDM	Non-insulin-dependent diabetes mellitus
TcPO ₂	Transcutaneous oxygen pressure
HBO	Hyperbaric oxygen

References

- Xie, T.; Ye, J.; Rerkasem, K.; Mani, R. The venous ulcer continues to be a clinical challenge: An update. *Burn. Trauma* **2018**, *6*, 18. [[CrossRef](#)] [[PubMed](#)]
- Saeedi, P.; Petersohn, I.; Salpea, P.; Malanda, B.; Karuranga, S.; Unwin, N.; Colagiuri, S.; Guariguata, L.; Motala, A.A.; Ogurtsova, K.; et al. Global and regional diabetes prevalence estimates for 2019 and projections for 2030 and 2045: Results from the International Diabetes Federation Diabetes Atlas, 9(th) edition. *Diabetes Res. Clin. Pract.* **2019**, *157*, 107843. [[CrossRef](#)]
- Li, Z.; Lin, F.; Thalib, L.; Chaboyer, W. Global prevalence and incidence of pressure injuries in hospitalised adult patients: A systematic review and meta-analysis. *Int. J. Nurs. Stud.* **2020**, *105*, 103546. [[CrossRef](#)]
- Martinengo, L.; Olsson, M.; Bajpai, R.; Soljak, M.; Upton, Z.; Schmidtchen, A.; Car, J.; Jarbrink, K. Prevalence of chronic wounds in the general population: Systematic review and meta-analysis of observational studies. *Ann. Epidemiol.* **2019**, *29*, 8–15. [[CrossRef](#)]
- Sen, C.K. Human Wound and Its Burden: Updated 2022 Compendium of Estimates. *Adv. Wound Care* **2023**, *12*, 657–670. [[CrossRef](#)]
- Heyer, K.; Herberger, K.; Protz, K.; Glaeske, G.; Augustin, M. Epidemiology of chronic wounds in Germany: Analysis of statutory health insurance data. *Wound Repair Regen.* **2016**, *24*, 434–442. [[CrossRef](#)] [[PubMed](#)]
- Olsson, M.; Jarbrink, K.; Divakar, U.; Bajpai, R.; Upton, Z.; Schmidtchen, A.; Car, J. The humanistic and economic burden of chronic wounds: A systematic review. *Wound Repair Regen.* **2019**, *27*, 114–125. [[CrossRef](#)] [[PubMed](#)]
- Ferreira, M.C.; Tuma, P., Jr.; Carvalho, V.F.; Kamamoto, F. Complex wounds. *Clinics* **2006**, *61*, 571–578. [[CrossRef](#)]
- Bowering, C.K. Diabetic foot ulcers. Pathophysiology, assessment, and therapy. *Can. Fam. Physician* **2001**, *47*, 1007–1016. [[PubMed](#)]
- Abbade, L.P.; Lastoria, S. Venous ulcer: Epidemiology, physiopathology, diagnosis and treatment. *Int. J. Dermatol.* **2005**, *44*, 449–456. [[CrossRef](#)]
- Edwards, R.; Harding, K.G. Bacteria and wound healing. *Curr. Opin. Infect. Dis.* **2004**, *17*, 91–96. [[CrossRef](#)]
- Ovington, L. Bacterial toxins and wound healing. *Ostomy. Wound. Manag.* **2003**, *49*, 8–12.
- Robson, M.C.; Stenberg, B.D.; Heggers, J.P. Wound healing alterations caused by infection. *Clin. Plast. Surg.* **1990**, *17*, 485–492. [[CrossRef](#)]
- Laato, M.; Niinikoski, J.; Lundberg, C.; Gerdin, B. Inflammatory reaction and blood flow in experimental wounds inoculated with *Staphylococcus aureus*. *Eur. Surg. Res.* **1988**, *20*, 33–38. [[CrossRef](#)] [[PubMed](#)]
- Polefka, T.G.; Bianchini, R.J.; Shapiro, S. Interaction of mineral salts with the skin: A literature survey. *Int. J. Cosmet. Sci.* **2012**, *34*, 416–423. [[CrossRef](#)] [[PubMed](#)]

16. Uauy, R.; Olivares, M.; Gonzalez, M. Essentiality of copper in humans. *Am. J. Clin. Nutr.* **1998**, *67*, 952S–959S. [[CrossRef](#)] [[PubMed](#)]
17. Vetchy, M.P.J.V. Biological role of copper as an essential trace element in the human organism. *Ceska. Slov. Farm* **2018**, *67*, 143–153. [[PubMed](#)]
18. Harris, E.D. A requirement for copper in angiogenesis. *Nutr. Rev.* **2004**, *62*, 60–64. [[CrossRef](#)] [[PubMed](#)]
19. Borkow, G.; Gabbay, J.; Zatzoff, R.C. Could chronic wounds not heal due to too low local copper levels? *Med. Hypotheses* **2008**, *70*, 610–613. [[CrossRef](#)] [[PubMed](#)]
20. Kornblatt, A.P.; Nicoletti, V.G.; Travaglia, A. The neglected role of copper ions in wound healing. *J. Inorg. Biochem.* **2016**, *161*, 1–8. [[CrossRef](#)] [[PubMed](#)]
21. La, M.D.; Arnesano, F.; Hansson, O.; Giacomelli, C.; Calo, V.; Mangini, V.; Magri, A.; Bellia, F.; Trincavelli, M.L.; Martini, C.; et al. Copper binding to naturally occurring, lactam form of angiogenin differs from that to recombinant protein, affecting their activity. *Metallomics* **2016**, *8*, 118–124. [[CrossRef](#)]
22. Narayanan, G.; Bharathidevi, S.R.; Vuyyuru, H.; Muthuvel, B.; Natrajan, S.N. CTR1 silencing inhibits angiogenesis by limiting copper entry into endothelial cells. *PLoS ONE* **2013**, *8*, e71982. [[CrossRef](#)]
23. Philips, N.; Samuel, P.; Parakandi, H.; Gopal, S.; Siomyk, H.; Ministro, A.; Thompson, T.; Borkow, G. Beneficial regulation of fibrillar collagens, heat shock protein-47, elastin fiber components, transforming growth factor-beta1, vascular endothelial growth factor and oxidative stress effects by copper in dermal fibroblasts. *Connect. Tissue Res.* **2012**, *53*, 373–378. [[CrossRef](#)] [[PubMed](#)]
24. Prudovsky, I.; Mandinova, A.; Soldi, R.; Bagala, C.; Graziani, I.; Landriscina, M.; Tarantini, F.; Duarte, M.; Bellum, S.; Doherty, H.; et al. The non-classical export routes: FGF1 and IL-1alpha point the way. *J. Cell Sci.* **2003**, *116*, 4871–4881. [[CrossRef](#)]
25. Sen, C.K.; Khanna, S.; Venojarvi, M.; Trikha, P.; Ellison, E.C.; Hunt, T.K.; Roy, S. Copper-induced vascular endothelial growth factor expression and wound healing. *Am. J. Physiol. Heart Circ. Physiol.* **2002**, *282*, H1821–H1827. [[CrossRef](#)] [[PubMed](#)]
26. Gerard, C.; Bordeleau, L.J.; Barralet, J.; Doillon, C.J. The stimulation of angiogenesis and collagen deposition by copper. *Biomaterials* **2010**, *31*, 824–831. [[CrossRef](#)] [[PubMed](#)]
27. Ogen-Shtern, N.; Chumin, K.; Cohen, G.; Borkow, G. Increased pro-collagen 1, elastin, and TGF-beta1 expression by copper ions in an ex-vivo human skin model. *J. Cosmet. Dermatol.* **2020**, *19*, 1522–1527. [[CrossRef](#)] [[PubMed](#)]
28. Tsai, C.Y.; Finley, J.C.; Ali, S.S.; Patel, H.H.; Howell, S.B. Copper influx transporter 1 is required for FGF, PDGF and EGF-induced MAPK signaling. *Biochem. Pharmacol.* **2012**, *84*, 1007–1013. [[CrossRef](#)]
29. Kothapalli, C.R.; Ramamurthi, A. Copper nanoparticle cues for biomimetic cellular assembly of crosslinked elastin fibers. *Acta Biomater.* **2009**, *5*, 541–553. [[CrossRef](#)]
30. Rucker, R.B.; Kosonen, T.; Clegg, M.S.; Mitchell, A.E.; Rucker, B.R.; Uriu-Hare, J.Y.; Keen, C.L. Copper, lysyl oxidase, and extracellular matrix protein cross-linking. *Am. J. Clin. Nutr.* **1998**, *67*, 996S–1002S. [[CrossRef](#)]
31. Sajithlal, G.B.; Chithra, P.; Chandrakasan, G. An in vitro study on the role of metal catalyzed oxidation in glycation and crosslinking of collagen. *Mol. Cell Biochem.* **1999**, *194*, 257–263. [[CrossRef](#)]
32. Tenaud, I.; Sainte-Marie, I.; Jumbou, O.; Litoux, P.; Dreno, B. In vitro modulation of keratinocyte wound healing integrins by zinc, copper and manganese. *Br. J. Dermatol.* **1999**, *140*, 26–34. [[CrossRef](#)]
33. Canapp, S.O., Jr.; Farese, J.P.; Schultz, G.S.; Gowda, S.; Ishak, A.M.; Swaim, S.F.; Vangilder, J.; Lee-Ambrose, L.; Martin, F.G. The effect of topical tripeptide-copper complex on healing of ischemic open wounds. *Vet. Surg.* **2003**, *32*, 515–523. [[CrossRef](#)] [[PubMed](#)]
34. Philips, N.; Hwang, H.; Chauhan, S.; Leonardi, D.; Gonzalez, S. Stimulation of cell proliferation and expression of matrixmetalloproteinase-1 and interleukin-8 genes in dermal fibroblasts by copper. *Connect. Tissue Res.* **2010**, *51*, 224–229. [[CrossRef](#)] [[PubMed](#)]
35. Simeon, A.; Emonard, H.; Hornebeck, W.; Maquart, F.X. The tripeptide-copper complex glycyl-L-histidyl-L-lysine-Cu²⁺ stimulates matrix metalloproteinase-2 expression by fibroblast cultures. *Life Sci.* **2000**, *67*, 2257–2265. [[CrossRef](#)]
36. Zhang, Y.; Mo, Y.; Zhang, Y.; Yuan, J.; Zhang, Q. MMP-3-mediated cleavage of OPN is involved in copper oxide nanoparticle-induced activation of fibroblasts. *Part. Fibre Toxicol.* **2023**, *20*, 22. [[CrossRef](#)] [[PubMed](#)]
37. Hong, M.; Gui, Y.; Xu, J.; Zhao, X.; Jiang, C.; Zhao, J.; Xin, X.; Liu, D.; Tang, X.; Tang, R.; et al. Palmitoyl copper peptide and acetyl tyrosine complex enhances melanin production in both A375 and B16 cell lines. *Biochem. Biophys. Res. Commun.* **2024**, *742*, 151060. [[CrossRef](#)]
38. Zhang, M.; Yao, A.; Ai, F.; Lin, J.; Fu, Q.; Wang, D. Cobalt-containing borate bioactive glass fibers for treatment of diabetic wound. *J. Mater. Sci. Mater. Med.* **2023**, *34*, 42. [[CrossRef](#)] [[PubMed](#)]
39. Solanki, A.K.; Lali, F.V.; Autefage, H.; Agarwal, S.; Nommeots-Nomm, A.; Metcalfe, A.D.; Stevens, M.M.; Jones, J.R. Bioactive glasses and electrospun composites that release cobalt to stimulate the HIF pathway for wound healing applications. *Biomater. Res.* **2021**, *25*, 1. [[CrossRef](#)]
40. Hodgkinson, V.; Petris, M.J. Copper homeostasis at the host-pathogen interface. *J. Biol. Chem.* **2012**, *287*, 13549–13555. [[CrossRef](#)]

41. Porcheron, G.; Garenaux, A.; Proulx, J.; Sabri, M.; Dozois, C.M. Iron, copper, zinc, and manganese transport and regulation in pathogenic Enterobacteria: Correlations between strains, site of infection and the relative importance of the different metal transport systems for virulence. *Front. Cell. Infect. Microbiol.* **2013**, *3*, 90. [[CrossRef](#)]
42. Borkow, G. Using copper to fight microorganisms. *Curr. Chem. Biol.* **2012**, *6*, 93–103. [[CrossRef](#)]
43. Borkow, G.; Gabbay, J. Copper as a biocidal tool. *Curr. Med. Chem.* **2005**, *12*, 2163–2175. [[CrossRef](#)] [[PubMed](#)]
44. Hazel, J.R.; Williams, E.E. The role of alterations in membrane lipid composition in enabling physiological adaptation of organisms to their physical environment. *Prog. Lipid Res.* **1990**, *29*, 167–227. [[CrossRef](#)]
45. Dean, R.T.; Wolff, S.P.; McElligott, M.A. Histidine and proline are important sites of free radical damage to proteins. *Free Radic. Res. Commun.* **1989**, *7*, 97–103. [[CrossRef](#)] [[PubMed](#)]
46. Davies, M.J.; Gilbert, B.C.; Haywood, R.M. Radical-induced damage to proteins: E.s.r. spin-trapping studies. *Free Radic. Res. Commun.* **1991**, *15*, 111–127. [[CrossRef](#)] [[PubMed](#)]
47. Borkow, G.; Okon-Levy, N.; Gabbay, J. Copper oxide impregnated wound dressings: Biocidal and safety studies. *Wounds* **2010**, *22*, 310–316.
48. Borkow, G.; Roth, T.; Kalinkovich, A. Wide spectrum potent antimicrobial efficacy of wound dressings impregnated with cuprous oxide microparticles. *Microbiol. Res.* **2022**, *13*, 29. [[CrossRef](#)]
49. Borkow, G.; Gabbay, J.; Dardik, R.; Eidelman, A.I.; Lavie, Y.; Grunfeld, Y.; Ikher, S.; Huszar, M.; Zatzoff, R.C.; Marikovsky, M. Molecular mechanisms of enhanced wound healing by copper oxide-impregnated dressings. *Wound Repair Regen.* **2010**, *18*, 266–275. [[CrossRef](#)] [[PubMed](#)]
50. Hong, W.X.; Hu, M.S.; Esquivel, M.; Liang, G.Y.; Rennert, R.C.; McArdle, A.; Paik, K.J.; Duscher, D.; Gurtner, G.C.; Lorenz, H.P.; et al. The Role of Hypoxia-Inducible Factor in Wound Healing. *Adv. Wound Care* **2014**, *3*, 390–399. [[CrossRef](#)] [[PubMed](#)]
51. Xu, X.W.; Zhang, J.; Guo, Z.W.; Song, M.M.; Sun, R.; Jin, X.Y.; Su, J.D.; Sun, B.W. A narrative review of research progress on the relationship between hypoxia-inducible factor-2alpha and wound angiogenesis. *Ann. Palliat. Med.* **2021**, *10*, 4882–4888. [[CrossRef](#)]
52. Xing, D.; Liu, L.; Marti, G.P.; Zhang, X.; Reinblatt, M.; Milner, S.M.; Harmon, J.W. Hypoxia and hypoxia-inducible factor in the burn wound. *Wound Repair Regen.* **2011**, *19*, 205–213. [[CrossRef](#)] [[PubMed](#)]
53. Feng, W.; Ye, F.; Xue, W.; Zhou, Z.; Kang, Y.J. Copper regulation of hypoxia-inducible factor-1 activity. *Mol. Pharmacol.* **2009**, *75*, 174–182. [[CrossRef](#)] [[PubMed](#)]
54. Wu, Z.; Zhang, W.; Kang, Y.J. Copper affects the binding of HIF-1alpha to the critical motifs of its target genes. *Metallomics* **2019**, *11*, 429–438. [[CrossRef](#)] [[PubMed](#)]
55. Zhu, D.; Wei, W.; Zhang, J.; Zhao, B.; Li, Q.; Jin, P. Mechanism of damage of HIF-1 signaling in chronic diabetic foot ulcers and its related therapeutic perspectives. *Heliyon* **2024**, *10*, e24656. [[CrossRef](#)] [[PubMed](#)]
56. Saber, S.; Abdelhady, R.; Elhemely, M.A.; Elmorsy, E.A.; Hamad, R.S.; Abdel-Reheim, M.A.; El-kott, A.F.; AlShehri, M.A.; Morsy, K.; Negm, S.; et al. Nanoscale Systems for Local Activation of Hypoxia-Inducible Factor-1 Alpha: A New Approach in Diabetic Wound Management. *Int. J. Nanomed.* **2024**, *19*, 13735–13762. [[CrossRef](#)] [[PubMed](#)]
57. Thangarajah, H.; Vial, I.N.; Grogan, R.H.; Yao, D.; Shi, Y.; Januszzyk, M.; Galiano, R.D.; Chang, E.I.; Galvez, M.G.; Glotzbach, J.P.; et al. HIF-1alpha dysfunction in diabetes. *Cell Cycle* **2010**, *9*, 75–79. [[CrossRef](#)]
58. Li, H.; Wu, Q.Y.; Teng, X.H.; Li, Z.P.; Zhu, M.T.; Gu, C.J.; Chen, B.J.; Xie, Q.Q.; Lu, O.X. The pathogenesis and regulatory role of HIF-1 in rheumatoid arthritis. *Cent. Eur. J. Immunol.* **2023**, *48*, 338–345. [[CrossRef](#)]
59. Das, A.; Sudhakar, V.; Chen, G.F.; Kim, H.W.; Youn, S.W.; Finney, L.; Vogt, S.; Yang, J.; Kweon, J.; Surenkhuu, B.; et al. Endothelial Antioxidant-1: A Key Mediator of Copper-dependent Wound Healing in vivo. *Sci. Rep.* **2016**, *6*, 33783. [[CrossRef](#)]
60. Coger, V.; Million, N.; Rehbock, C.; Sures, B.; Nachev, M.; Barcikowski, S.; Wistuba, N.; Straub, S.; Vogt, P.M. Tissue concentration of zinc, iron, copper, and magnesium during the phases of full thickness wound healing in a rodent model. *Biol. Trace Elem. Res.* **2019**, *191*, 167–176. [[CrossRef](#)]
61. Lansdown, A.B.; Sampson, B.; Rowe, A. Sequential changes in trace metal, metallothionein and calmodulin concentrations in healing skin wounds. *J. Anat.* **1999**, *195 Pt 3*, 375–386. [[CrossRef](#)]
62. Yi, W.J.; Yuan, Y.; Bao, Q.; Zhao, Z.; Ding, H.S.; Song, J. Analyzing Immune Cell Infiltration and Copper Metabolism in Diabetic Foot Ulcers. *J. Inflamm. Res.* **2024**, *17*, 3143–3157. [[CrossRef](#)] [[PubMed](#)]
63. Yadav, C.; Srikantiah, R.M.; Manjrekar, P.; Shenoy, M.T.; Chaudhury, D. Assessment of mineral pathophysiology in patients with diabetic foot ulcers. *Biol. Trace Elem. Res.* **2020**, *195*, 366–372. [[CrossRef](#)] [[PubMed](#)]
64. Zhang, Z.; Xue, H.; Xiong, Y.; Geng, Y.; Panayi, A.C.; Knoedler, S.; Dai, G.; Shahbazi, M.A.; Mi, B.; Liu, G. Copper incorporated biomaterial-based technologies for multifunctional wound repair. *Theranostics* **2024**, *14*, 547–570. [[CrossRef](#)]
65. Diao, W.; Li, P.; Jiang, X.; Zhou, J.; Yang, S. Progress in copper-based materials for wound healing. *Wound Repair Regen.* **2024**, *32*, 314–322. [[CrossRef](#)]
66. Lencina, M.M.S.; Brugnoli, L.I.; Ninago, M.D.; Villar, M.A.; Vega, D.A.; Del Barrio, M.C. Enhanced antibacterial activity of starch-alginate beads by a synergistic effect between Cu²⁺ and Zn²⁺ ions with a potential wound dressing application. *Int. J. Biol. Macromol.* **2024**, *280*, 135798. [[CrossRef](#)]

67. Astaneh, M.E.; Fereydouni, N. Advancing diabetic wound care: The role of copper-containing hydrogels. *Heliyon* **2024**, *10*, e38481. [[CrossRef](#)] [[PubMed](#)]
68. Butsyk, A.; Moskalenko, R. Novel copper-loaded dressing for wound healing: A bibliometric analysis. *Odessa Med. J.* **2024**, *3*, 72–78. [[CrossRef](#)]
69. Kohoolat, G.; Alizadeh, P.; Motesadi Zarandi, F.; Rezaeipour, Y. A ternary composite hydrogel based on sodium alginate, carboxymethyl cellulose and copper-doped 58S bioactive glass promotes cutaneous wound healing in vitro and in vivo. *Int. J. Biol. Macromol.* **2024**, *259*, 129260. [[CrossRef](#)]
70. Zhao, S.; Li, L.; Wang, H.; Zhang, Y.; Cheng, X.; Zhou, N.; Rahaman, M.N.; Liu, Z.; Huang, W.; Zhang, C. Wound dressings composed of copper-doped borate bioactive glass microfibers stimulate angiogenesis and heal full-thickness skin defects in a rodent model. *Biomaterials* **2015**, *53*, 379–391. [[CrossRef](#)]
71. Lemraski, E.G.; Jahangirian, H.; Dashti, M.; Khajehali, E.; Sharafinia, S.; Rafiee-Moghaddam, R.; Webster, T.J. Antimicrobial Double-Layer Wound Dressing Based on Chitosan/Polyvinyl Alcohol/Copper: In vitro and in vivo Assessment. *Int. J. Nanomed.* **2021**, *16*, 223–235. [[CrossRef](#)] [[PubMed](#)]
72. Alizadeh, S.; Seyedalipour, B.; Shafieyan, S.; Kheime, A.; Mohammadi, P.; Aghdami, N. Copper nanoparticles promote rapid wound healing in acute full thickness defect via acceleration of skin cell migration, proliferation, and neovascularization. *Biochem. Biophys. Res. Commun.* **2019**, *517*, 684–690. [[CrossRef](#)] [[PubMed](#)]
73. Alizadeh, S.; Samadikuchaksaraei, A.; Jafari, D.; Orive, G.; Dolatshahi-Pirouz, A.; Pezeshki-Modaress, M.; Gholipourmalek-abadi, M. Enhancing Diabetic Wound Healing Through Improved Angiogenesis: The Role of Emulsion-Based Core-Shell Micro/Nanofibrous Scaffold with Sustained CuO Nanoparticle Delivery. *Small* **2024**, *20*, e2309164. [[CrossRef](#)] [[PubMed](#)]
74. Quan, M.; Li, J.; Cui, M.; Sha, G.; Wang, Y.; Wu, B.; Zhu, J.; Chen, J. Copper peroxide-loaded lignin-based non-isocyanate polyurethane foam for wound repair applications. *Int. J. Biol. Macromol.* **2024**, *288*, 138733. [[CrossRef](#)]
75. Gopal, A.; Kant, V.; Gopalakrishnan, A.; Tandan, S.K.; Kumar, D. Chitosan-based copper nanocomposite accelerates healing in excision wound model in rats. *Eur. J. Pharmacol.* **2014**, *731*, 8–19. [[CrossRef](#)] [[PubMed](#)]
76. Kumar, A.; Pandit, V.; Nagaich, U. Therapeutic evaluation of chemically synthesized copper nanoparticles to promote full-thickness excisional wound healing. *Int. J. Appl. Pharm.* **2020**, *12*, 136–142. [[CrossRef](#)]
77. Tang, Q.; Tan, Y.; Leng, S.; Liu, Q.; Zhu, L.; Wang, C. Cupric-polymeric nanoreactors integrate into copper metabolism to promote chronic diabetic wounds healing. *Mater. Today Bio* **2024**, *26*, 101087. [[CrossRef](#)] [[PubMed](#)]
78. Huang, W.; Xu, P.; Fu, X.; Yang, J.; Jing, W.; Cai, Y.; Zhou, Y.; Tao, R.; Yang, Z. Functional molecule-mediated assembled copper nanozymes for diabetic wound healing. *J. Nanobiotechnology* **2023**, *21*, 294. [[CrossRef](#)]
79. Dai, S.; Jiang, L.; Liu, L.; Su, Z.; Yao, L.; Yang, P.; Huang, N. MOF-encapsulated copper-doped carbon dots nanozymes with excellent biological activity promote diabetes wound healing. *Regen. Biomater.* **2024**, *11*, rbae119. [[CrossRef](#)] [[PubMed](#)]
80. Li, Q.; Xiao, X.; Yan, T.; Song, D.; Li, L.; Chen, Z.; Zhong, Y.; Deng, W.; Liu, X.; Song, Y.; et al. Heterojunction Nanozyme Hydrogels Containing Cu-O-Zn Bonds with Strong Charge Transfer for Accelerated Diabetic Wound Healing. *ACS Appl. Mater. Interfaces* **2024**, *16*, 68950–68966. [[CrossRef](#)] [[PubMed](#)]
81. Hou, B.; Li, C.; Yang, F.; Deng, W.; Hu, C.; Liu, C.; Chen, Y.; Xiao, X.; Huang, X.; Deng, J.; et al. Ultrasmall Antioxidant Copper Nanozyme to Enhance Stem Cell Microenvironment for Promoting Diabetic Wound Healing. *Int. J. Nanomed.* **2024**, *19*, 13563–13578. [[CrossRef](#)] [[PubMed](#)]
82. Zhang, C.; Zhang, X.; Li, F.; Li, B.; Zhang, M.; Li, W.; Zhuge, P.; Yao, J.; Zhang, Y.; Chen, S.; et al. Thermosensitive Hydrogel Integrated with Bimetallic Nano-Enzymes for Modulating the Microenvironment in Diabetic Wound Beds. *Adv. Sci.* **2024**, *12*, e2411575. [[CrossRef](#)] [[PubMed](#)]
83. Ali, A.M.; Elkhoully, G.E.; Orabi, A.; Ismail, A.; Barbosa, R.M.; Riela, S.; Viseras, C.; Abo-zeid, Y. Optimization of Chemical Synthesis for Production of a Skin-Compatible and Scalable Copper Oxide Nanoparticles: A Promising and Safe Strategy for Healing of Non-infected and Infected Wounds in Diabetes. *BioNanoScience* **2025**, *15*, 141. [[CrossRef](#)]
84. Zhang, Z.; Chang, D.; Zeng, Z.; Xu, Y.; Yu, J.; Fan, C.; Yang, C.; Chang, J. CuCS/Cur composite wound dressings promote neuralized skin regeneration by rebuilding the nerve cell “factory” in deep skin burns. *Mater. Today Bio* **2024**, *26*, 101075. [[CrossRef](#)] [[PubMed](#)]
85. Shtapenko, O.; Syrvatka, V.; Horbay, R.; Dzen, Y.; Slyvchuk, O.; Gromyko, O.; Gevkan, I. Evaluation of Antimicrobial Activity and in Vivo Wound Healing Properties of Copper Nanoparticles and Copper Nanoparticles Nanoemulsion. *Biointerface Res. Appl. Chem.* **2024**, *14*, 1–11. [[CrossRef](#)]
86. Wang, F.; Zheng, Y.; Ning, J. Biogenic preparation of copper oxide nanoparticles using table olive: Catalytic reduction, cytotoxicity, and burn wound healing activities. *Environ. Res.* **2023**, *237*, 116995. [[CrossRef](#)] [[PubMed](#)]
87. Salvo, J.; Sandoval, C.; Schencke, C.; Acevedo, F.; Del Sol, M. Healing Effect of a Nano-Functionalized Medical-Grade Honey for the Treatment of Infected Wounds. *Pharmaceutics* **2023**, *15*, 2187. [[CrossRef](#)] [[PubMed](#)]

88. Ruggeri, M.; Nomicisio, C.; Taviot-Guého, C.; Vigani, B.; Boselli, C.; Grisoli, P.; Cornaglia, A.I.; Bianchi, E.; Viseras, C.; Rossi, S.; et al. Smart copper-doped clays in biomimetic microparticles for wound healing and infection control. *Mater. Today Bio* **2024**, *29*, 101292. [[CrossRef](#)]
89. Ermini, M.L.; Summa, M.; Zamborlin, A.; Frusca, V.; Mapanao, A.K.; Mugnaioli, E.; Bertorelli, R.; Voliani, V. Copper nano-architecture topical cream for the accelerated recovery of burnt skin. *Nanoscale Adv.* **2023**, *5*, 1212–1219. [[CrossRef](#)]
90. Sun, W.; Lu, H.; Zhang, P.; Zeng, L.; Ye, B.; Xu, Y.; Chen, J.; Xue, P.; Yu, J.; Chen, K.; et al. Localized propranolol delivery from a copper-loaded hydrogel for enhancing infected burn wound healing via adrenergic β -receptor blockade. *Mater. Today Bio* **2025**, *30*, 101417. [[CrossRef](#)] [[PubMed](#)]
91. Yang, J.; Huang, Z.; Tan, J.; Pan, J.; Chen, S.; Wan, W. Copper ion/gallic acid MOFs-laden adhesive pomelo peel sponge effectively treats biofilm-infected skin wounds and improves healing quality. *Bioact. Mater.* **2024**, *32*, 260–276. [[CrossRef](#)]
92. Wang, M.; Zhang, W.; Wang, C.; Xiao, L.; Yu, L.; Fan, J. Hemostatic and antibacterial calcium-copper zeolite gauze for infected wound healing. *RSC Adv.* **2024**, *14*, 878–888. [[CrossRef](#)] [[PubMed](#)]
93. Zhang, H.; Bai, J.; Chen, X.; Wang, L.; Peng, W.; Zhao, Y.; Weng, J.; Zhi, W.; Wang, J.; Zhang, K.; et al. Constructing a highly efficient multifunctional carbon quantum dot platform for the treatment of infectious wounds. *Regen. Biomater.* **2024**, *11*, rbae105. [[CrossRef](#)] [[PubMed](#)]
94. Cui, H.; Liu, M.; Yu, W.; Cao, Y.; Zhou, H.; Yin, J.; Liu, H.; Que, S.; Wang, J.; Huang, C.; et al. Copper Peroxide-Loaded Gelatin Sponges for Wound Dressings with Antimicrobial and Accelerating Healing Properties. *ACS Appl. Mater. Interfaces* **2021**, *13*, 26800–26807. [[CrossRef](#)] [[PubMed](#)]
95. Tao, B.; Lin, C.; Deng, Y.; Yuan, Z.; Shen, X.; Chen, M.; He, Y.; Peng, Z.; Hu, Y.; Cai, K. Copper-nanoparticle-embedded hydrogel for killing bacteria and promoting wound healing with photothermal therapy. *J. Mater. Chem. B* **2019**, *7*, 2534–2548. [[CrossRef](#)]
96. Liu, Y.; Zhao, Y.; Guo, S.; Qin, D.; Yan, J.; Cheng, H.; Zhou, J.; Ren, J.; Sun, L.; Peng, H.; et al. Copper doped carbon dots modified bacterial cellulose with enhanced antibacterial and immune regulatory functions for accelerating wound healing. *Carbohydr. Polym.* **2024**, *346*, 122656. [[CrossRef](#)] [[PubMed](#)]
97. Li, Y.; Lu, J.; Shi, J.; Zhang, L.; Mu, H.; Cui, T. Carboxymethyl chitosan nanoparticle-modulated cationic hydrogels doped with copper ions for combating bacteria and facilitating wound healing. *Front. Bioeng. Biotechnol.* **2024**, *12*, 1429771. [[CrossRef](#)] [[PubMed](#)]
98. Zhou, Y.; Gao, S.; Zhou, J.; He, Q.; Yuan, X.; Guo, J.; Yan, F. Cu-BTC MOFs Grown In Situ on Poly(ionic liquid)-Based Electrospun Fibrous Membranes for Wound Dressings. *ACS Appl. Polym. Mater.* **2024**, *6*, 14410–14420. [[CrossRef](#)]
99. Li, L.; Ren, A.; Zhao, Q.; Xu, K.; Wu, Q.; Su, Q.; Li, X.; Lü, L.; Wang, L. Gallic acid-grafted chitosan photothermal hydrogels functionalized with mineralized copper-sericin nanoparticles for MRSA-infected wound management. *Carbohydr. Polym.* **2025**, *352*, 123179. [[CrossRef](#)] [[PubMed](#)]
100. Fu, X.; Du, S.; Liang, J.; Wang, B.; Liu, Y.; Yu, Y.; Xu, L.; Xue, P.; Wang, B.; Kang, Y. Nanoscale coordination polymer-coated microneedle patches against bacterial biofilm infection via hypoxia-enhanced copper ion interference therapy. *Chem. Eng. J.* **2024**, *504*, 158789. [[CrossRef](#)]
101. Luo, B.; Xiong, Y.; Cai, J.; Jiang, R.; Li, Y.; Xu, C.; Wang, X. Chitin-Assisted Synthesis of CuS Composite Sponge for Bacterial Capture and Near-Infrared-Promoted Healing of Infected Diabetic Wounds. *ACS Appl. Mater. Interfaces* **2024**, *16*, 50160–50174. [[CrossRef](#)] [[PubMed](#)]
102. Sheng, L.; Feng, Y.; Wu, S.; Wang, C.; Sun, R.; Jin, Q.; Chen, D.; Zhang, Z.; Xu, H.; Dong, Z.; et al. Biodegradable copper vanadate-based hydrogel with photocatalytic/photothermal therapy for infected diabetic wound healing. *Mater. Des.* **2024**, *246*, 113358. [[CrossRef](#)]
103. Zhang, R.; Jiang, G.; Gao, Q.; Wang, X.; Wang, Y.; Xu, X.; Yana, W.; Shen, H. Sprayed copper peroxide nanodots for accelerating wound healing in a multidrug-resistant bacteria infected diabetic ulcer. *Nanoscale* **2021**, *13*, 15937–15951. [[CrossRef](#)] [[PubMed](#)]
104. Ghosh, D.; Godeshala, S.; Nitiyanandan, R.; Islam, M.S.; Yaron, J.R.; DiCaudo, D.; Kilbourne, J.; Rege, K. Copper-Eluting Fibers for Enhanced Tissue Sealing and Repair. *ACS Appl. Mater. Interfaces* **2020**, *12*, 27951–27960. [[CrossRef](#)] [[PubMed](#)]
105. Sandoval, C.; Rios, G.; Sepulveda, N.; Salvo, J.; Souza-Mello, V.; Farias, J. Effectiveness of Copper Nanoparticles in Wound Healing Process Using In Vivo and In Vitro Studies: A Systematic Review. *Pharmaceutics* **2022**, *14*, 1838. [[CrossRef](#)]
106. Wang, W.; Gao, P.; Gui, H.; Wei, X.; Zhang, H.; Wang, X. Copper-based nanomaterials for the treatment of bacteria-infected wounds: Material classification, strategies and mechanisms. *Coord. Chem. Rev.* **2025**, *522*, 216205. [[CrossRef](#)]
107. Borkow, G.; Melamed, E. Copper, an abandoned player returning to the wound healing battle. In *Recent Advances in Wound Healing*; Aghaei, S., Ed.; IntechOpen London: London, UK, 2021; pp. 165–184.
108. Melamed, E.; Borkow, G. Continuum of care in hard-to-heal wounds by copper dressings: A case series. *J. Wound Care* **2023**, *32*, 788–796. [[CrossRef](#)] [[PubMed](#)]
109. Melamed, E.; Kiambi, P.; Okoth, D.; Honigber, I.; Tamir, E.; Borkow, G. Healing of Chronic Wounds by Copper Oxide-Impregnated Wound Dressings-Case Series. *Medicina* **2021**, *57*, 296. [[CrossRef](#)] [[PubMed](#)]

110. Melamed, E.; Rovitsky, A.; Roth, T.; Assa, L.; Borkow, G. Stimulation of Healing of Non-Infected Stagnated Diabetic Wounds by Copper Oxide-Impregnated Wound Dressings. *Medicina* **2021**, *57*, 1129. [[CrossRef](#)]
111. Melamed, E.; Rovitsky, A.; Roth, T.; Borkow, G. Anterior ankle full thickness skin necrosis treated with copper oxide dressings without debridement and skin graft—A case report. *Arch. Clin. Med. Case Rep.* **2022**, *6*, 501–510. [[CrossRef](#)]
112. Weitman, C.C.; Roth, T.; Borkow, G. Copper dressings to the wound rescue after everything else failed: Case report. *Arch. Clin. Med. Case Rep.* **2022**, *6*, 466–473.
113. Gorel, O.; Hamuda, M.; Feldman, I.; Kucyn-Gabovich, I. Enhanced healing of wounds that responded poorly to silver dressing by copper wound dressings: Prospective single arm treatment study. *Health Sci. Rep.* **2024**, *7*, e1816. [[CrossRef](#)] [[PubMed](#)]
114. Lu, W.; Rao, A.; Oropallo, A.; Gawlik, S.; Haight, J. Use of Copper Nanoparticles to Reduce Bioburden in the Treatment of Diabetic Foot Ulcers. *Eplasty* **2022**, *22*, QA4. [[PubMed](#)]
115. Asakiene, I. Copper dressings—the most effective in treating chronic wounds. In Proceedings of the Vilnius Vascular Symposium, Vilnius, Lithuania, 3–4 October 2024.
116. Franolic, M.; Batinac, T.; Dujanic, V.; Sertic, S.; Pljesa, A.; Cosic, F.; Vukovic, Z.; Piplica, M.; Marcucci, E.; Radic, M.; et al. Application of antibacterial foam dressing with copper oxide for the treatment of chronic post-burn wounds. In Proceedings of the EWMA, London, UK, 1–3 May 2024.
117. Janssen, A.H.J.; Siebers, Y.H.P. Copper dressing resulting in increased oxygen levels in wound and surrounding skin. In Proceedings of the EWMA, London, UK, 1–3 May 2024.
118. Dokic, S.; Jovisic, I.; Frangez, I. Wound dressing with the addition of copper. In Proceedings of the EWMA, Milan, Italy, 3–5 May 2023.
119. Corsi, A.; Forma, A.; Lupi, S.M.; Vidotto, G.; Aloise, A.; Ognibene, L.; Cazzaro, U.; De Angelis, G.; Gianluca, B.; Pitoia, G. Copper dressings: Much more than an antimicrobial. In Proceedings of the EWMA, Milan, Italy, 3–5 May 2023.
120. Treadwell, T.; Nikolaychuk, L.; Baker, J.; Pickens, A. The Use of Copper Oxide Impregnated Dressings in the Treatment of Hard to Heal Acute and Chronic Wounds. In Proceedings of the SAWC, Las Vegas, NV, USA, 13–16 October 2022.
121. Steward, L.; Brunette, G.; Crookes, K.; Fite, K.; Hinson, L.; Miller, C.; Ross, J. Novel Copper Dressing with a recalcitrant sickle cell ulceration. In Proceedings of the SAWC, Las Vegas, NV, USA, 2–5 November 2023.
122. Melamed, E.; Dabbah, J.; Israel, T.; Kan, I.; Pinzur, M.S.; Roth, T.; Borkow, G. Non-inferiority of copper dressings compared to negative pressure wound therapy (NPWT) in diabetic foot—A randomized control trial. In Proceedings of the EWMA, Barcelona, Spain, 26–28 March 2025.

Disclaimer/Publisher’s Note: The statements, opinions and data contained in all publications are solely those of the individual author(s) and contributor(s) and not of MDPI and/or the editor(s). MDPI and/or the editor(s) disclaim responsibility for any injury to people or property resulting from any ideas, methods, instructions or products referred to in the content.